



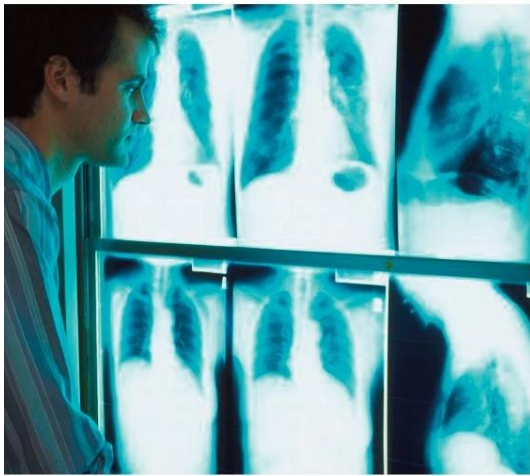


NBME

National Board of Medical Examiners

WWW.NBME.ORG

SUBJECT EXAMINATIONS



CONTENT OUTLINES AND SAMPLE ITEMS

TABLE OF CONTENTS

BASIC SCIENCES	
<i>Behavioral Sciences</i>	3
<i>Biochemistry</i>	10
<i>Gross Anatomy and Embryology</i>	16
<i>Histology and Cell Biology</i>	22
<i>Microbiology</i>	28
<i>Neuroscience</i>	34
<i>Pathology</i>	40
<i>Pharmacology</i>	46
<i>Physiology</i>	52
CLINICAL SCIENCES	
<i>Clinical Neurology</i>	58
<i>Family Medicine</i>	65
<i>Medicine</i>	72
<i>Obstetrics and Gynecology</i>	79
<i>Pediatrics</i>	85
<i>Psychiatry</i>	92
<i>Surgery</i>	99
COMPREHENSIVE BASIC SCIENCE	105
COMPREHENSIVE CLINICAL SCIENCE	111
INTRODUCTION TO CLINICAL DIAGNOSIS	118
ADULT AMBULATORY MEDICINE	124
ADULT/PEDIATRIC AMBULATORY MEDICINE	128
FAMILY MEDICINE MODULAR	131
EMERGENCY MEDICINE ADVANCED CLINICAL	135
INTERNAL MEDICINE ADVANCED CLINICAL	139
SURGERY ADVANCED CLINICAL	143
PEDIATRICS ADVANCED CLINICAL	147

BEHAVIORAL SCIENCES

Progression through life cycle	1%–5%
Psychological and social factors influencing patient behavior	5%–10%
Patient interviewing, consultation, and interactions with the family	10%–15%
Medical ethics, jurisprudence, and professional behavior	5%–10%
Nutrition including vitamin deficiencies and eating disorders	1%–5%
Central & peripheral nervous systems	50%–55%
Normal processes (brain stem, brain, motor systems, autonomic nervous systems)	5%–10%
Psychopathologic disorders	30%–40%
Principles of therapy and pharmacodynamic general principles	5%–10%
Gender, ethnic, and behavioral considerations affecting disease treatment and prevention (including psychosocial, cultural, occupational, and environmental)	5%–10%

1. A 50-year-old man develops difficulty walking while receiving drug therapy for paranoid behavior. Physical examination shows masked facies and diffuse muscle rigidity. He is slow in initiating movement and walks with a shuffling narrow-based gait. Which of the following drugs is the most likely cause of these findings?

 - (A) Barbiturate
 - (B) Benzodiazepine
 - (C) Monoamine oxidase inhibitor
 - (D) Phenothiazine
 - (E) Tricyclic compound
2. A 24-year-old man is brought to the emergency department by his mother after barricading himself in his apartment. For 8 months, he has believed that aliens follow him and control his mind. He was fired from his part-time job 6 months ago because of unusual behavior. There are no other apparent psychosocial stressors. His paternal grandmother has major depressive disorder. He does not use drugs, but his mother states that he frequently drinks beer. There is no disturbance of mood, sleep, or appetite. Examination shows an extremely agitated and suspicious patient. There is a 1 × 1-cm abrasion in the right frontal area. His blood alcohol concentration is 0.5 mg/dL, and serum γ -glutamyltransferase (GGT) activity is 40 U/L (N=5–50). Which of the following is the most likely diagnosis?

 - (A) Alcohol-induced mood disorder
 - (B) Bipolar disorder, manic
 - (C) Brief psychotic disorder
 - (D) Schizoaffective disorder
 - (E) Schizophrenia, paranoid type
3. A 43-year-old woman is brought to the emergency department 1 hour after a stranger stole her purse. She is agitated and extremely upset. She is 163 cm (5 ft 4 in) tall and weighs 91 kg (200 lb); BMI is 34 kg/m². Physical examination shows no other abnormalities. Her blood glucose concentration is increased. Which of the following is the most likely explanation for this finding?

 - (A) β -Cell hypersecretion
 - (B) Cushing disease
 - (C) Glucagon-secreting adenoma
 - (D) Pancreatitis
 - (E) Normal stress hormone response
4. A 4-year-old girl is brought to the physician by her mother because of a fever for 1 day. The physician is more than 1 hour behind schedule because of two patient emergencies earlier that day. When he enters the room, the mother yells, “Do you know how long we’ve had to wait? This is totally unacceptable!” It is most appropriate for the physician to initially state which of the following?

 - (A) “I am frustrated, too, with being so far behind schedule.”
 - (B) “I hope my staff explained about the difficult patients who caused the delay.”
 - (C) “It must have been very difficult to be here for so long with a sick child.”
 - (D) “My office staff scheduled too many patients for today.”
 - (E) “Unfortunately, some patients demand more time than we scheduled for them.”

5. A 45-year-old man is admitted to the hospital because of chest pain for 1 hour. He has a sedentary lifestyle, and his diet is high in fat and sodium. The diagnosis of acute angina is made, and the appropriate treatment is administered. After the patient's condition is stabilized, the physician recommends an exercise regimen and a low-fat, low-sodium diet. Two weeks later, the patient returns for a follow-up examination. He indicates that he has not yet returned to work and spends most of the day lying on the couch. He has not had any chest pain, shortness of breath, dyspnea with exertion, or peripheral edema. Which of the following initial statements by the physician is most appropriate?
- "Are you afraid you might have a heart attack if you exercise?"
 - "Are you doing any types of exercise other than channel surfing?"
 - "Have you also not been following the diet I recommended?"
 - "What do you think is interfering with your ability to resume activity?"
 - "When would you like to start working on improving your health?"
6. A firstborn 1-year-old girl is hospitalized for evaluation of arrested growth. Pregnancy and delivery were uncomplicated, and development was normal initially. The infant is listless and has a diaper rash. She is below the 5th percentile for length and weight. No other abnormalities are noted. After 1 week of routine hospital care, the infant has gained 1 kg (2.2 lb) and has become more responsive. Which of the following is the most likely explanation for the arrested growth?
- Hypothyroidism
 - Infantile psoriasis
 - Milk allergy
 - Parental neglect
 - Pyloric stenosis
7. A 15-year-old boy with generalized tonic-clonic seizures is brought to the physician by his mother for a follow-up examination. She says he has not been taking his medication regularly. In his presence, she explains to the physician that she is baffled by her son's behavior and "can't get him to take his pills, let alone take out the trash." Even after his mother leaves, the patient stares out the window and refuses to talk. Which of the following behaviors during the interview is most appropriate to assess the patient's compliance with this regimen?
- Confront the patient about his poor behavior
 - Explain the patient's resistance to him
 - Laugh and joke with the patient
 - Project a firm, businesslike manner
 - Project a respectful, tolerant attitude and encourage free discussion
8. The children of a 67-year-old woman ask their family physician for advice about their mother's behavior 4 weeks after the death of her husband of 40 years. They are concerned because she weeps whenever she comes upon an object in her home that she associates with him. Her appetite has decreased, and she has had a 2-kg (4.4-lb) weight loss. She awakens 1 hour before the alarm goes off each morning. She is able to care for herself. Although she does not leave her home for any social activities, she does enjoy visits from her family. Which of the following is the most likely explanation and appropriate management?
- Normal grief reaction, and she requires no medical attention
 - Normal grief reaction, and she would benefit from diazepam therapy
 - Pathologic grief reaction, and she should be treated with an antidepressant
 - Pathologic grief reaction, and she should be treated with psychotherapy
 - Pathologic grief reaction, and she should be encouraged to move in with one of her children
9. A 4-year-old girl is brought to the physician because she consistently uses her left hand. Her mother, who is also left-handed, tells the physician that she wants her daughter to be right-handed because she resents all the obstacles she faced as a left-handed child. She makes her daughter practice with a crayon held only in her right hand. Which of the following responses by the physician is most appropriate?
- "I know you want the best for your daughter, but pressing her to change is unlikely to work and might cause its own problems."
 - "I understand your concerns, and since she is only 4, your efforts will likely result in her being right-handed by age 7 years."
 - "Times have changed. There is much less discrimination against left-handed people now."
 - "You may be causing irreversible psychological trauma to your child, which could be worse than being left-handed."
 - "You shouldn't interfere with nature."

10. A 65-year-old man comes to the physician for a follow-up examination after the results of a bronchoscopy showed squamous cell carcinoma. When the physician tells the patient the diagnosis, the patient becomes tearful and responds, "No, you're wrong! This must be a mistake. This can't happen to me. Let's do more tests." This patient is most likely at which of the following stages of grief?
- (A) Anger
 - (B) Bargaining
 - (C) Denial
 - (D) Depression
11. A 10-month-old boy is brought to the emergency department by his babysitter 1 hour after he was difficult to arouse following a head injury. The babysitter says he hit his head after falling off a bed and that she could not wake him at first when she found him lying on the floor. The patient is conscious and not in distress. Physical examination shows a 2-cm hematoma over the left parietal region of the head. There are ecchymoses in various stages of healing on different body surfaces, including the buttocks and low back. Neurologic examination shows no abnormalities. When questioned about the bruises, the babysitter replies, "He just seems to bruise easily. Maybe he has some sort of bleeding problem." After notifying the parents, the physician should do which of the following next?
- (A) Ask the hospital social worker to obtain a criminal background check on the babysitter
 - (B) Have a court appoint a guardian for the child
 - (C) Notify child protective services of suspected abuse
 - (D) Refer the patient to a pediatric hematologist
 - (E) Register a formal complaint against the babysitter with the local police department
12. A 10-year-old girl is brought to the physician by her parents for a well-child examination. When alone with the physician, the parents state that they are concerned because some of her friends seem overly preoccupied with food when they are visiting. Their daughter also has begun to show an interest in fashion magazines and stylish clothing. Although their daughter has had consistent and appropriate weight gain throughout her life, the parents are aware of the risks for eating disorders and are eager to do anything they can to avoid such a problem. It is most appropriate for the physician to recommend which of the following to the parents regarding their daughter?
- (A) Encourage more family meals
 - (B) Forbid access to fashion magazines
 - (C) Have her eat more at every meal
 - (D) Suggest she prepare her own meals
 - (E) Weigh her weekly
13. A 46-year-old man comes to the physician for a follow-up examination. He underwent coronary artery bypass grafting 3 weeks ago. He works long hours daily as the head chef and owner of a restaurant. He has had a 14-kg (30-lb) weight gain since opening his restaurant 3 years ago. He attributes this weight gain to "working around food all day, every day." He does not smoke cigarettes. His father had a myocardial infarction at the age of 60 years. The patient is 175 cm (5 ft 9 in) tall and now weighs 102 kg (225 lb); BMI is 33 kg/m². Physical examination shows no other abnormalities. He tells the physician that he is afraid to cut down on his work hours because his business might suffer as a result, but he says, "I don't want to have a heart attack like my dad did." Which of the following responses by the physician is most appropriate?
- (A) "The fact that you do not smoke cigarettes balances out your other risk factors, such as your weight and family history."
 - (B) "Given your family history, modifying other risk factors won't have much impact."
 - (C) "I suggest you have someone else run your business for the time being, so you can spend your days in a more healthy environment."
 - (D) "Let's discuss some lifestyle changes, including weight loss, exercise, and decreased stress."
 - (E) "Since the only risk factor for a myocardial infarction you can change is your weight, I suggest you initiate a weight-loss program fairly soon."
14. A 40-year-old woman with hypertension comes to the physician for a follow-up examination. Her blood pressure is 160/96 mm Hg. She tells the physician that she has been having difficulty being compliant with her medication regimen and low-sodium diet. Which of the following responses by the physician is most appropriate?
- (A) "I will go over the regimen and diet again to make sure you understand them."
 - (B) "I'd like you to read these pamphlets on the risks of hypertension. You will then realize the seriousness of your condition."
 - (C) "If you don't follow my recommendations, you could end up having a heart attack or stroke. You could also become blind."
 - (D) "Tell me the difficulties you've been having. Perhaps we can make your regimen and diet easier for you to follow."
 - (E) "Unfortunately, if you do not follow your medication regimen and diet, I will find it difficult to act as your physician."

15. A 27-year-old woman comes to the physician because of an itchy rash on her hands for 2 weeks. She states that she began training as a hairstylist 3 weeks ago and works 6 hours daily, cutting, coloring, and highlighting hair and giving perms. Examination of the hands shows edema with weepy vesicular lesions in a glove pattern bilaterally. Which of the following initial actions by the physician is most appropriate?
- (A) Advise the patient to stop her training and look for another type of job
 - (B) Immediately irrigate the affected area with copious amounts of water and prescribe an anti-inflammatory ointment
 - (C) Inform the patient that her lesions are consistent with poison ivy dermatitis and determine when and where she was exposed
 - (D) Prescribe oral corticosteroid treatment and tell the patient to avoid giving perms since harsh chemicals are involved
 - (E) Prescribe topical corticosteroid treatment and advise the patient to wear non-latex gloves at work
16. A 42-year-old man with mild mental retardation comes to his primary care physician for a follow-up examination. The patient has received care from this physician for many years. He recently received the diagnosis of inoperable retroperitoneal sarcoma. His prognosis is poor. He serves as his own guardian and lives independently. His oncologist recommends chemotherapy that is highly toxic and has less than a 5% response rate for this type of tumor. The primary care physician believes that the burden of suffering clearly outweighs the limited potential benefit of this treatment. The patient says that he is unsure whether he wishes to undergo the chemotherapy. Which of the following is the most appropriate next step by the primary care physician?
- (A) Ask the patient what he understands about the treatment and its likely effects
 - (B) Contact the oncologist and request that he reconsider this treatment plan
 - (C) Emphasize the toxic adverse effects of the treatment and how uncomfortable the patient would be
 - (D) Encourage the patient to allow the primary care physician to decide what is best for him
 - (E) Stress the extremely low chance that treatment will provide any benefit to the patient
17. A 5-year-old boy with Down syndrome is admitted to the hospital because of a 1-month history of fatigue, intermittent fever, and weakness. Results from a peripheral blood smear taken during his evaluation are indicative of possible acute lymphoblastic leukemia. The physician recommends a bone marrow aspiration to confirm the diagnosis and subsequent cytogenetic studies as needed. The patient's parents refuse to consent to the procedure because they think such an invasive test will cause their son too much unnecessary pain. Without confirmation of the diagnosis and results from cytogenetic testing, the patient's treatment may be adversely affected. Which of the following is the most appropriate next step for the physician?
- (A) Accede to the parents' wishes to spare their son further pain
 - (B) Consult child protective services
 - (C) Discuss options to manage the potential pain during the procedure
 - (D) Do the necessary procedure despite the parents' objections
 - (E) Explain that the child will die if the procedure is refused
18. A 70-year-old man with terminal pancreatic cancer is admitted to the hospital because of severe shortness of breath. He has no documented advance care plans. His three children tell the physician that they want everything possible to be done for their father, including cardiopulmonary resuscitation (CPR) and intubation, if necessary. The patient is cachectic and unaware of his surroundings. Which of the following initial responses by the physician is most appropriate?
- (A) "I hear you, and I understand how difficult it must be for you to see your father ill. Let's talk more about the options."
 - (B) "I know that you are distressed about your father's illness, but you must accept that he will die soon."
 - (C) "I want you to reconsider your decision about CPR and intubation. Your father's prognosis is very poor."
 - (D) "Relatives in this type of situation feel distressed, and they want to prolong the life of their loved one unnecessarily."
 - (E) "You are just prolonging the inevitable. Your father is going to die."

19. A 32-year-old woman comes to the emergency department after taking 40 1-mg tablets of alprazolam. She says that her boyfriend threatened to leave her, and she feels “empty.” She drinks several six-packs of beer weekly and uses cocaine daily. She has outbursts of rage whether or not she is intoxicated. Which of the following is the most likely personality disorder?

- (A) Antisocial
- (B) Borderline
- (C) Dependent
- (D) Narcissistic

20. A 34-year-old woman with major depressive disorder comes to the physician for a follow-up examination. She says that her depressive symptoms are worsening. Multiple medication regimens have been ineffective. The patient says that she spoke recently with a former college roommate who also has depression. Her friend is currently enrolled in a clinical trial for a new antidepressant at a local center. The patient says, “My friend seems to be doing really well with this new medication, and I think I’d like to try it out to see if it would work for me, too. Can you write me a referral to the center where my friend is enrolled?” Which of the following is the most appropriate initial response by the physician to this patient’s request?

- (A) Decline to refer the patient because she has treatment-refractory depression that typically is not accepted into clinical trials
- (B) Discuss the conduct of clinical trials so that the patient has a clear understanding of how they operate
- (C) Inform the patient that she cannot receive future care from the physician if she enrolls in the clinical trial
- (D) Inform the patient that she will not get the best care possible if she enrolls in an experimental trial
- (E) Refer the patient to the center because so many other treatment options have failed

Answer Form for Behavioral Science Sample Questions

(Questions 1-20)

1. _____
2. _____
3. _____
4. _____
5. _____
6. _____
7. _____
8. _____
9. _____
10. _____

11. _____
12. _____
13. _____
14. _____
15. _____
16. _____
17. _____
18. _____
19. _____
20. _____

Answer Key for Behavioral Science Sample Questions

(Questions 1-20)

- | | | | |
|-----|---|-----|---|
| 1. | D | 11. | C |
| 2. | E | 12. | A |
| 3. | E | 13. | D |
| 4. | C | 14. | D |
| 5. | D | 15. | E |
| 6. | D | 16. | A |
| 7. | E | 17. | C |
| 8. | A | 18. | A |
| 9. | A | 19. | B |
| 10. | C | 20. | B |

BIOCHEMISTRY

Gene expression: DNA structure, replication, and exchange	5%–10%
Gene expression: transcription (including defects)	5%–10%
Gene expression: translation (including defects)	5%–10%
Structure and function of proteins	5%–10%
Energy metabolism	15%–20%
Metabolic pathways of small molecules	15%–20%
Biology of cells	5%–10%
Human development and genetics	1%–5%
Biology of tissue response to disease	1%–5%
Nutrition	5%–10%
Pharmacodynamic and pharmacokinetic processes	1%–5%
Normal processes	10%–15%
Hematopoietic & lymphoreticular system	1%–5%
Central & peripheral nervous system	1%–5%
Endocrine system	5%–10%

- In order to determine the rate of DNA synthesis in various mammalian tissues, the administration of which of the following labeled substances would be most specific in labeling DNA?
 - Adenosine
 - Cytosine
 - Guanosine
 - Thymidine
 - Uridine
- A 2-year-old boy who recently emigrated from Somalia is brought to the physician because of a 1-day history of pain of his arms and legs. Physical examination shows pale mucous membranes and hepatosplenomegaly. Laboratory studies show a hemoglobin concentration of 8 g/dL. A peripheral blood smear shows sickle cells. Genetic analyses show a point mutation in the β -globin gene leading to a change of a GAG codon (glutamate) to a GUG codon (valine). Which of the following anticodons is most likely in the tRNA for valine?
 - CAC
 - CTU
 - CUC
 - GAC
 - GCC
- Which of the following post-translational modifications is most likely to be found on a cyclin B protein that is targeted for degradation?
 - Acetylated lysine residues
 - Phosphorylated serine residues
 - Phosphorylated threonine residues
 - Phosphorylated tyrosine residues
 - Ubiquitinated lysine residues
- A previously healthy 16-year-old girl is brought to the physician because of abdominal cramps, bloating, and loose stools for 6 months. These symptoms began after she ingested skim milk in an attempt to lose weight. She is at the 50th percentile for height and 75th percentile for weight. Physical examination shows no abnormalities. Stool studies show a 3+ Clinitest reagent response and pH of 5. After the patient ingests milk, there is an increased hydrogen concentration in expired air. A deficiency of which of the following enzyme activities is the most likely cause of the gastrointestinal symptoms in this patient?
 - Amylase
 - Carboxypeptidase
 - Fructose-1,6-bisphosphate aldolase
 - Galactokinase
 - Lactase
 - Sucrase

5. A married couple is screened to assess the risk for Gaucher disease in their children. The activities of glucocerebrosidase in the sera of the mother and father are 45% and 55%, respectively, of the reference value. The couple has one child. Which of the following is the probability of the child possessing one or more alleles of the Gaucher mutation?
- (A) 0
(B) 0.25
(C) 0.5
(D) 0.75
(E) 1.0
6. The release of epinephrine from the chromaffin granules of the adrenal medulla into the bloodstream in response to neural stimulation is mediated by which of the following?
- (A) Acetylcholine
(B) γ -Aminobutyric acid (GABA)
(C) Cortisol
(D) Dopamine
(E) Serotonin
7. During normal screening for phenylketonuria, a male newborn has a serum phenylalanine concentration of 35 mg/dL (greater than 20 mg/dL is considered a positive test). Signs of tyrosine deficiency also are apparent. Enzymatic analysis using cultured fibroblasts, obtained after circumcision, shows normal activity of phenylalanine hydroxylase. A possible explanation for these findings is a deficiency in function of which of the following coenzymes?
- (A) Adenosylcobalamin
(B) Biopterin
(C) Dihydroquinone
(D) Pyridoxal phosphate
(E) Tetrahydrofolic acid
8. A 2-year-old boy with mental retardation has chewed the tips of his fingers on both hands and a portion of his lower lip. His serum uric acid concentration is increased, and he has a history of uric acid renal calculi. His 5-year-old brother has similar findings. Which of the following abnormal enzyme activities is the most likely cause of these findings?
- (A) Decreased adenine phosphoribosyltransferase
(B) Decreased adenosine deaminase
(C) Decreased hypoxanthine-guanine phosphoribosyltransferase
(D) Increased phosphoribosylpyrophosphate synthetase
(E) Increased xanthine oxidase
9. A 14-year-old girl is brought to the physician because of a recent growth spurt of 15 cm (6 in) during the past year. She also has had increasing fatigue and palpitations during this period. Her paternal aunt has a history of palpitations and severe myopia. She is at the 95th percentile for height and 50th percentile for weight. Physical examination shows a long, thin face. Ophthalmologic examination shows dislocated lenses. Cardiac examination shows a hyperdynamic precordium with early click and systolic murmur. Echocardiography shows an enlarged aortic root and mitral valve prolapse. Abnormal synthesis of which of the following proteins is the most likely cause of this patient's disorder?
- (A) Collagen, type I
(B) Elastin
(C) Fibrillin-1
(D) Fibroblast growth factor R3
(E) Laminin
(F) Neurofibromin
(G) PAX 6
10. Native collagen is composed almost entirely of which of the following types of structures?
- (A) α -Helix
(B) β -Pleated sheet
(C) Random coils
(D) Triple helix
(E) Two peptides connected by a disulfide bond
11. An otherwise healthy 20-year-old woman of Mediterranean descent is given sulfamethoxazole to treat a bladder infection. Three days after beginning the antibiotic regimen, the patient has moderately severe jaundice and dark urine. Pain with urination and a low-grade fever have resolved. Her hematocrit is 20%. Substantial numbers of erythrocytes contain Heinz bodies. Her condition worsens until day 6 of antibiotic therapy, when it begins to resolve. Symptoms are completely gone by day 9 of continued antibiotic therapy. Which of the following conditions is the most likely explanation for these findings?
- (A) Aplastic anemia
(B) Generalized cytochrome-*b*₅ reductase deficiency
(C) Glucose-6-phosphate dehydrogenase deficiency
(D) Pyruvate kinase deficiency
(E) Systemic infection cured by antibiotic therapy

12. A 45-year-old woman has the sudden onset of severe headaches. During one of these episodes, her blood pressure is 190/115 mm Hg. Her usual blood pressure is 130/90 mm Hg. Her sister had similar episodes several years ago. Urinalysis shows increased concentrations of metanephrine and vanillylmandelic acid. The patient is most likely to have a neoplasm that secretes which of the following?
- ACTH
 - Aldosterone
 - Cortisol
 - Epinephrine
 - Renin
13. An inherited disorder of carbohydrate metabolism is characterized by an abnormally increased concentration of hepatic glycogen with normal structure and no detectable increase in serum glucose concentration after oral administration of fructose. These two observations suggest that the disease is a result of the absence of which of the following enzymes?
- Fructokinase
 - Glucokinase
 - Glucose-6-phosphatase
 - Phosphoglucomutase
 - UDP glucose
14. A 15-year-old girl limits her diet to carrots, tomatoes, green vegetables, bread, pasta, rice, and skim milk. She has an increased risk for vitamin A deficiency because its absorption requires the presence of which of the following?
- Heme
 - Intrinsic factor
 - Phosphatidylcholine
 - Protein
 - Triglyceride
15. An increased concentration of fructose 2,6-bisphosphate in hepatocytes will have a positive regulatory effect on which of the following?
- Gluconeogenesis and glucose-6-phosphatase
 - Gluconeogenesis and phosphoenolpyruvate carboxykinase
 - Glycolysis and glucokinase
 - Glycolysis and phosphofructokinase 1
16. During the processing of particular N-linked glycoproteins, residues of mannose 6-phosphate are generated. Which of the following proteins is most likely to undergo this step in processing?
- Apo B receptor
 - The citrate transport protein of the inner mitochondrial membrane
 - IgG
 - Lysosomal α -fucosidase
 - Mitochondrial isocitrate dehydrogenase
17. A 65-year-old man with coronary artery disease comes to the physician for a follow-up examination. He is 183 cm (6 ft) tall and weighs 84 kg (185 lb); BMI is 25 kg/m². His blood pressure is 130/80 mm Hg. The lungs are clear to auscultation. Cardiac examination shows no point of maximal impulse. Serum studies show a glucose concentration of 95 mg/dL and homocysteine concentration of 19.3 μ mol/L (N=5–15). Serum lipid concentrations are within the reference range. Which of the following amino acids is most likely to be decreased in this patient?
- Arginine
 - Leucine
 - Lysine
 - Methionine
 - Ornithine
18. Which of the following is required to transport fatty acids across the inner mitochondrial membrane?
- Acyl carrier protein
 - Albumin
 - Carnitine
 - Chylomicrons
 - Creatinine
 - Lecithin-cholesterol acyltransferase
19. Failure to bind LDL to its receptor results in uncontrolled synthesis of cholesterol. This occurs because synthesis of which of the following enzymes is not repressed?
- Acyl CoA cholesterol acyltransferase
 - 3-Hydroxy-3-methylglutaryl (HMG)-CoA reductase
 - Lecithin-cholesterol acyltransferase
 - Lipoprotein lipase
 - Lysosomal protease

20. A 67-year-old man has a restricted diet that includes no fresh citrus fruits or leafy green vegetables. His teeth are loose and his gums bleed easily. This patient's disorder most likely results from a defect in collagen synthesis that involves which of the following amino acids?
- (A) Arginine
 - (B) Cysteine
 - (C) Histidine
 - (D) Hydroxyproline
 - (E) Leucine
 - (F) Methionine
 - (G) Serine
 - (H) Tryptophan

Answer Form for Biochemistry Sample Questions

(Questions 1-20)

1. _____
2. _____
3. _____
4. _____
5. _____
6. _____
7. _____
8. _____
9. _____
10. _____

11. _____
12. _____
13. _____
14. _____
15. _____
16. _____
17. _____
18. _____
19. _____
20. _____

Answer Key for Biochemistry Sample Questions

(Questions 1-20)

- | | | | |
|-----|---|-----|---|
| 1. | D | 11. | C |
| 2. | A | 12. | D |
| 3. | E | 13. | C |
| 4. | E | 14. | E |
| 5. | D | 15. | D |
| 6. | A | 16. | D |
| 7. | B | 17. | D |
| 8. | C | 18. | C |
| 9. | C | 19. | B |
| 10. | D | 20. | D |

GROSS ANATOMY AND EMBRYOLOGY

System

General Principles: Human Development and Genetics	1%–5%
Individual Organ Systems	95%–99%
Hematopoietic & lymphoreticular	1%–5%
Central & peripheral nervous	15%–20%
Skin & related connective tissue	1%–5%
Musculoskeletal	15%–20%
Respiratory	5%–10%
Cardiovascular	5%–10%
Gastrointestinal	5%–10%
Renal/urinary	5%–10%
Reproductive	5%–10%
Endocrine	5%–10%

Process

Normal	75%–80%
Abnormal	20%–25%

1. A 45-year-old woman has a uterine leiomyoma that is 5 cm in diameter and is pressing on the urinary bladder, causing urinary frequency. Which of the following is the most likely location of the leiomyoma?
 - (A) Cervical canal
 - (B) Lateral margin of the uterine cavity
 - (C) Subendometrially in the uterine cavity
 - (D) Subperitoneally on the anterior surface of the uterine corpus
 - (E) Subperitoneally on the posterior surface of the uterine fundus
2. A 5-year-old girl is brought to the emergency department because of fever and severe abdominal pain. Acute appendicitis is diagnosed. In the examination room, she keeps her right hip flexed and resists active extension of the hip. The inflamed structure associated with these symptoms is most likely in contact with which of the following structures?
 - (A) Abdominal wall and the external oblique muscle
 - (B) Obturator internus muscle
 - (C) Psoas major muscle
 - (D) Quadratus lumborum muscle
 - (E) Transversus abdominis muscle
3. A 61-year-old man comes to the physician because of a 3-month history of episodes of headache, heart palpitations, and excessive sweating. He has had a 10-kg (22-lb) weight loss during this period. While being examined, during an episode his blood pressure is 210/110 mm Hg. Physical examination shows no other abnormalities. Urine studies show increased catecholamine concentrations. A CT scan of the abdomen is most likely to show a mass in which of the following locations?
 - (A) Adrenal glands
 - (B) Appendix
 - (C) Kidneys
 - (D) Pancreas
 - (E) Stomach
4. A 6-year-old boy has a large intra-abdominal mass in the midline just above the symphysis pubis. During an operation, a cystic mass is found attached to the umbilicus and the apex of the bladder. Which of the following is the most likely diagnosis?
 - (A) Hydrocele
 - (B) Meckel cyst
 - (C) Meckel diverticulum
 - (D) Omphalocele
 - (E) Urachal cyst

5. A 55-year-old man who has alcoholic cirrhosis is brought to the emergency department because he has been vomiting blood for 2 hours. He has a 2-month history of abdominal distention, dilated veins over the anterior abdominal wall, and internal hemorrhoids. Which of the following veins is the most likely origin of the hematemesis?
- (A) Inferior mesenteric veins
 - (B) Left gastric vein
 - (C) Periumbilical veins
 - (D) Superior rectal vein
 - (E) Superior vena cava
6. A 3-year-old girl with mild craniofacial dysmorphism has profound hearing deficits. Further evaluation indicates profound sensory auditory deficits and vestibular problems. Altered development of which of the following is most likely to account for these observations?
- (A) Ectodermal placode
 - (B) Intermediate mesoderm
 - (C) Lateral plate mesoderm
 - (D) Neural crest cell
 - (E) Paraxial mesoderm
 - (F) Prochordal mesoderm
7. A 19-year-old woman comes to the physician because of a 5-day history of increasingly severe right lower abdominal pain and bloody vaginal discharge. Her last menstrual period was 8 weeks ago. Abdominal examination shows exquisite tenderness of the right lower quadrant. A serum pregnancy test result is positive. Ultrasonography shows no gestational sac in the uterus. Which of the following is the most likely location of this patient's fertilized egg?
- (A) Cervix
 - (B) Peritoneum of the right lower abdominal wall
 - (C) Rectouterine pouch (of Douglas)
 - (D) Right fallopian tube
 - (E) Right ovary
8. A 22-year-old man is brought to the emergency department because of a suprahyoid stab wound that extends from one side of the neck to the other. His tongue deviates to the right when protruded; there is no loss of sensory modality on the tongue. The injury most likely involves which of the following nerves?
- (A) Left hypoglossal
 - (B) Left vagus
 - (C) Right hypoglossal
 - (D) Right glossopharyngeal
 - (E) Right lingual
9. A 45-year-old woman is found to have adenocarcinoma of the left breast. Resection of the tumor is scheduled, and the physician also plans to obtain samples of the draining nodes. To find these nodes, a radiotracer is injected adjacent to the tumor and images are obtained. The first draining sentinel node in this patient is most likely found at which of the following locations?
- (A) Contralateral neck
 - (B) Ipsilateral axilla
 - (C) Ipsilateral mediastinum
 - (D) Ipsilateral supraclavicle
 - (E) Medial contralateral breast
10. A 3629-g (8-lb) male newborn is delivered at term. During the initial examination, urine is found to be leaking from the umbilicus. This patient most likely has an abnormality of which of the following fetal structures?
- (A) Umbilical arteries
 - (B) Umbilical vein
 - (C) Urachus
 - (D) Urogenital sinus
 - (E) Urorectal septum
11. A 70-year-old man has a 90% blockage at the origin of the inferior mesenteric artery. He does not have intestinal angina. Which of the following arteries is the most likely additional source of blood to the descending colon?
- (A) Left gastroepiploic
 - (B) Middle colic
 - (C) Sigmoid
 - (D) Splenic
 - (E) Superior rectal
12. A 30-year-old man comes to the emergency department 1 hour after injuring his left knee in a volleyball game. He says he twisted his left leg when he fell to the floor after he and a teammate accidentally collided. He cannot bear weight on his left leg. Physical examination shows tenderness and swelling of the left knee. When the patient sits on the edge of the examination table, the left knee can be displaced anteriorly at an abnormal degree. Which of the following is most likely injured in this patient?
- (A) Anterior cruciate ligament
 - (B) Fibular collateral ligament
 - (C) Menisiofemoral ligament
 - (D) Oblique popliteal ligament
 - (E) Transverse ligament of the knee

13. A 70-year-old man is brought to the emergency department because of a 1-week history of increasingly severe left-sided lower abdominal pain and passing gas in his urine. His temperature is 38.9°C (102°F). A CT scan of the abdomen shows gas in the bladder and edema of the fat surrounding the sigmoid colon. There is no obvious lymph node enlargement. Which of the following is the most likely cause of this patient's condition?
- (A) Appendicitis with fistula
 - (B) Bladder infection
 - (C) Diverticulitis with fistula
 - (D) Prostate cancer with fistula
 - (E) Urinary tract infection
14. A 60-year-old man has tenderness in the region distally between the tendons of the extensor pollicis longus and extensor pollicis brevis (anatomical snuffbox) after falling on the palm of his right hand. A fracture of which of the following carpal bones is most likely in this patient?
- (A) Hamate
 - (B) Lunate
 - (C) Scaphoid
 - (D) Trapezium
 - (E) Triquetrum
15. A 20-year-old man is brought to the emergency department 1 hour after he was involved in a motorcycle collision. He was not wearing a helmet. Physical examination shows clear fluid dripping from the nose. X-rays show a fracture of the cribriform plate of the ethmoid bone. This patient is at greatest risk for impairment of which of the following senses?
- (A) Balance
 - (B) Hearing
 - (C) Olfaction
 - (D) Taste from the anterior two thirds of the tongue
 - (E) Taste from the posterior one third of the tongue
 - (F) Vision
16. A 7-year-old boy tires easily while running. On auscultation, a harsh continuous murmur is heard at the left of the sternum between the first two ribs. Arterial blood oxygen content is slightly higher in the right hand than in the left hand. X-rays of the chest show no abnormalities. Which of the following is the most likely diagnosis?
- (A) Anomalous return of pulmonary blood to the right atrium
 - (B) Patent ductus arteriosus
 - (C) Patent foramen ovale
 - (D) Stenosis of the aortic valve
 - (E) Tricuspid atresia
17. A 50-year-old woman is brought to the emergency department because of severe upper abdominal pain for 24 hours. She has a 2-day history of intermittent fever and pale stools. Her temperature is 38.9°C (102°F), pulse is 120/min, respirations are 20/min, and blood pressure is 90/50 mm Hg. Physical examination shows jaundice and tenderness of the right upper quadrant of the abdomen. Serum studies show a bilirubin concentration of 5 mg/dL, alkaline phosphatase activity of 450 U/L, and lipase activity of 400 U/L (N=14–280). Which of the following is the most likely cause of this patient's symptoms?
- (A) Impaction of a gallstone in the hepatopancreatic ampulla
 - (B) Intestinal obstruction secondary to diverticulitis
 - (C) Pancreatic mucinous cystadenoma
 - (D) Penetration and perforation of a peptic ulcer
 - (E) Ulcerative colitis
18. A 6-year-old boy is brought to the physician by his parents for a follow-up examination because of a heart murmur that has been present since birth. His only symptom is fatigue. His pulse is 110/min, and blood pressure is 80/40 mm Hg. Physical examination shows no cyanosis or clubbing of the fingers. Cardiac examination shows a normal S₁ and a split S₂. A grade 3/6 pansystolic murmur is heard maximally at the lower left to mid left sternal border. He undergoes cardiac catheterization and is found to have a higher than expected oxygen level in the right ventricle. Which of the following is the most likely cause of these findings?
- (A) Coarctation of the aorta
 - (B) Congenital bicuspid aortic valve
 - (C) Pulmonary artery stenosis
 - (D) Tricuspid stenosis
 - (E) Ventricular septal defect
19. A 32-year-old woman, gravida 2, para 2, develops fever and left lower abdominal pain 3 days after delivery of a full-term male newborn. Abdominal examination shows a tender, palpable mass. Ultrasonography of the mass shows an ovarian vein thrombosis. The thrombus is most likely to extend into which of the following veins?
- (A) Hemiazygos vein
 - (B) Inferior vena cava
 - (C) Left internal iliac vein
 - (D) Left internal pudendal vein
 - (E) Left renal vein

20. During a study of bladder function, a healthy 20-year-old man drinks 1 L of water and delays urination for 30 minutes after feeling the urge to urinate. Which of the following muscles permits his voluntary control of micturition?
- (A) Coccygeus
 - (B) Detrusor
 - (C) External urethral sphincter
 - (D) Internal urethral sphincter
 - (E) Obturator internus

Answer Form for Gross Anatomy and Embryology Sample Questions

(Questions 1-20)

- | | |
|-----------|-----------|
| 1. _____ | 11. _____ |
| 2. _____ | 12. _____ |
| 3. _____ | 13. _____ |
| 4. _____ | 14. _____ |
| 5. _____ | 15. _____ |
| 6. _____ | 16. _____ |
| 7. _____ | 17. _____ |
| 8. _____ | 18. _____ |
| 9. _____ | 19. _____ |
| 10. _____ | 20. _____ |

Answer Key for Gross Anatomy and Embryology Sample Questions

(Questions 1-20)

- | | | | |
|-----|---|-----|---|
| 1. | D | 11. | B |
| 2. | C | 12. | A |
| 3. | A | 13. | C |
| 4. | E | 14. | C |
| 5. | B | 15. | C |
| 6. | D | 16. | B |
| 7. | D | 17. | A |
| 8. | C | 18. | E |
| 9. | B | 19. | E |
| 10. | C | 20. | C |

HISTOLOGY AND CELL BIOLOGY

<i>General Principles</i>	<i>30%–35%</i>
Biochemistry and molecular biology	1%–5%
Cell biology	25%–30%
Signal transduction	1%–5%
Cell components	5%–10%
Nucleus	1%–5%
Cytoskeleton	1%–5%
Secretion and exocytosis, endocytosis, transcytosis	1%–5%
Cell cycle, mitosis, meiosis	5%–10%
Epithelial cells	5%–10%
Muscle cells	1%–5%
Human development and genetics	1%–5%
Biology of tissue response	1%–5%
Immune responses	1%–5%
 <i>Organ Systems</i>	 <i>65%–70%</i>
Hematopoietic & lymphoreticular	1%–5%
Central & peripheral nervous	10%–15%
Skin & related connective tissue	5%–10%
Musculoskeletal	5%–10%
Respiratory	5%–10%
Cardiovascular	5%–10%
Gastrointestinal	5%–10%
Renal/urinary	5%–10%
Reproductive	5%–10%
Endocrine	5%–10%

1. An oophorectomized monkey is treated with high doses of estrogen. Which of the following changes is most likely to occur in the endometrium after 1 year of treatment?
 - (A) Atrophy
 - (B) Hyperplasia
 - (C) Hypertrophy
 - (D) Hypoplasia
 - (E) Metaplasia

2. Which of the following muscle cell components helps spread the depolarization of the muscle cell membranes throughout the interior of muscle cells?
 - (A) Actin
 - (B) Myosin
 - (C) T tubule
 - (D) Tropomyosin
 - (E) Troponin
 - (F) Z disk

3. A new drug is developed that prevents the demyelination occurring in the progress of multiple sclerosis. The drug protects the cells responsible for the synthesis and maintenance of myelin in the central nervous system. These cells are most likely which of the following?
 - (A) Astrocyte
 - (B) Ependymal cell
 - (C) Microglial cell
 - (D) Oligodendrocyte
 - (E) Schwann cell

4. A 10-year-old boy undergoes an appendectomy. Granulation tissue develops normally at the incision site. Tissue remodeling begins at this site with degradation of collagen in the extracellular matrix by which of the following proteins?
 - (A) Cytokines
 - (B) Lipoygenases
 - (C) Metalloproteinase
 - (D) Nitric oxide
 - (E) Plasminogen activator

5. In which of the following nuclear structures is DNA actively transcribed to rRNA?
- (A) Envelope
 - (B) Lamina
 - (C) Matrix
 - (D) Nucleolus
 - (E) Pore
6. A 22-year-old man is brought to the emergency department in respiratory distress 15 minutes after he was stung on the arm by a wasp. His pulse is 100/min, respirations are 30/min, and blood pressure is 100/60 mm Hg. Physical examination shows grunting respirations and subcostal retractions. Expiratory wheezes are heard over both lung fields. There is generalized urticaria. Secretion of the molecule causing this patient's symptoms is most likely mediated by which of the following?
- (A) Activation of complement
 - (B) Activation of mast cell
 - (C) Activation of T lymphocytes
 - (D) Production of IgA
 - (E) Production of IgG
 - (F) Production of IgM
7. A 66-year-old man with Zollinger-Ellison syndrome undergoes a gastrectomy. He is informed that he will require treatment with intramuscular vitamin B₁₂ (cyanocobalamin) for the rest of his life. This therapy is necessary because this patient lacks which of the following types of cells?
- (A) Chief
 - (B) G (gastrin)
 - (C) Goblet
 - (D) Mucous neck
 - (E) Parietal
8. Beginning with protein synthesis in membrane-bound ribosomes, hepatocytes secrete proteins into the circulation via which of the following mechanisms?
- (A) Active transport through the cell membrane
 - (B) Diffusion through the cell membrane
 - (C) Transport by microtubules and exocytosis
 - (D) Transport in vesicles and exocytosis
 - (E) Transport through pores in the cell membrane
9. Which of the following is required to transport fatty acids across the inner mitochondrial membrane?
- (A) Acyl carrier protein
 - (B) Albumin
 - (C) Carnitine
 - (D) Chylomicrons
 - (E) Creatinine
 - (F) Lecithin-cholesterol acyltransferase
10. An experiment is conducted in which the mitochondrial content of various tissues is studied. It is found that the mitochondrial content is directly proportional to the amount of energy one cell is required to generate and expend. The mitochondrial content is most likely greatest in which of the following types of cells?
- (A) Cardiac muscle cells
 - (B) Chondrocytes
 - (C) Endothelial cells
 - (D) Epidermal cells
 - (E) Hepatocytes
 - (F) Osteocytes
 - (G) White adipocytes
11. A 45-year-old man without a history of bleeding or excessive bruising dies suddenly due to rupture of an aortic dissection. Genetic analysis at autopsy shows a defect in the gene for fibrillin. Which of the following events most likely occurs with defective fibrillin?
- (A) Elastic fibers in the extracellular matrix are not correctly formed
 - (B) Hyaluronic acid in proteoglycans is not sulfated on the proper hydroxyl residues
 - (C) Intermediate filaments are not assembled in the endothelial cells
 - (D) Shorter side chains of chondroitin sulfate are present on proteoglycans
 - (E) Tubulin is not polymerized correctly due to the lack of GTP in endothelial cells
12. A 42-year-old woman comes to the physician for a follow-up examination after two separate Pap smears have shown dysplastic epithelial cells. Results of a molecular diagnostic test show DNA that encodes high-risk versions of the human papillomavirus E6 and E7 proteins. The viral E6 protein binds to the cellular p53 tumor suppressor gene, causing it to be degraded. Which of the following best describes the mechanism by which the E6 protein causes cervical cancer?
- (A) Arrests the cell cycle
 - (B) Enhances tissue invasion and metastasis
 - (C) Inhibits telomerase expression
 - (D) Prevents apoptosis
 - (E) Sustains angiogenesis

13. Which of the following is the correct sequence of events in the initiation of contraction of a skeletal muscle fiber?

	Depolarization of Sarcolemma	Conformational Change in Troponin-Tropomyosin Complex	Release of Ca ²⁺ from Sarcoplasmic Reticulum	Propagation into Transverse Tubules	Acetylcholine Binding to Receptors
(A)	1	2	3	4	5
(B)	2	5	4	3	1
(C)	3	5	2	4	1
(D)	4	2	5	3	1
(E)	5	3	4	1	2

14. A 90-year-old woman is brought to the emergency department 30 minutes after she fell while climbing the steps into her house. Physical examination shows tenderness over the right shin area. An x-ray of the right lower extremity shows a fracture of the tibia. A DEXA scan shows decreased bone density. Increased activity of which of the following cell types is the most likely cause of the decrease in bone mass in this patient?

- (A) Chondrocytes
- (B) Osteoblasts
- (C) Osteoclasts
- (D) Osteocytes
- (E) Osteoprogenitor cells

15. A 50-year-old man comes to the physician because of a cough productive of large quantities of mucus for 6 months. He has smoked 1 pack of cigarettes daily for 25 years. Which of the following cell types is the most likely cause of the increase in this patient's secretion of mucus?

- (A) Columnar ciliated epithelial cells
- (B) Goblet cells
- (C) Interstitial cells
- (D) Macrophages
- (E) Pneumocyte epithelial cells

16. A 65-year-old man with severe atherosclerotic coronary artery disease comes to the emergency department because of a 12-hour history of chest pain. Plasma activity of the MB isozyme of creatine kinase (MB-CK) is markedly increased. Which of the following processes is the most likely explanation for the increased plasma MB-CK?

- (A) Cell membrane damage
- (B) Endoplasmic reticulum dilation
- (C) Mitochondrial swelling
- (D) Polysome dissociation
- (E) Sodium pump dysfunction

17. During an experimental study, an investigator finds that the regulation of cell cycle and programmed cell death may be initiated by the mitochondrion. The interaction of the mitochondrion with the activation of the caspase family of proteases and subsequent apoptosis is most likely mediated by which of the following?

- (A) Calcium release
- (B) cAMP production
- (C) Cytochrome *c* release
- (D) GTP binding
- (E) Nitric oxide release

18. A 48-year-old man has hepatic cancer that is unresponsive to standard therapy. He enrolls in a clinical study of a novel chemotherapeutic agent that, as a side effect, blocks kinesin, a component of the cellular microtubular transport system. One week later, he develops skeletal muscle weakness. An alteration in which of the following components of the neuromuscular junction is the most likely cause of the muscle weakness?

- (A) A decrease in the number of postsynaptic neurotransmitter receptors
- (B) A decrease in the number of presynaptic neurotransmitter vesicles
- (C) A decrease in the presynaptic neuron calcium permeability
- (D) Impaired α -motoneuron action potential conduction
- (E) Impaired skeletal muscle action potential conduction

19. A polysome is actively involved in translation. The ribosomes are attached to which of the following?

- (A) Single-stranded DNA
- (B) Double-stranded DNA
- (C) mRNA
- (D) rRNA
- (E) tRNA

20. A pathologist uses monoclonal antibodies against several intermediate filament proteins and finds that a tumor section stains positive for cytokeratin only. The tumor most likely originated from which of the following tissues?
- (A) Connective
 - (B) Epithelial
 - (C) Glial
 - (D) Muscle
 - (E) Nermal

**Answer Form for Histology and Cell Biology Examination Sample
Questions**

(Questions 1-20)

- | | |
|-----------|-----------|
| 1. _____ | 11. _____ |
| 2. _____ | 12. _____ |
| 3. _____ | 13. _____ |
| 4. _____ | 14. _____ |
| 5. _____ | 15. _____ |
| 6. _____ | 16. _____ |
| 7. _____ | 17. _____ |
| 8. _____ | 18. _____ |
| 9. _____ | 19. _____ |
| 10. _____ | 20. _____ |

**Answer Key for Histology and Cell Biology Examination Sample
Questions**

(Questions 1-20)

- | | | | |
|-----|---|-----|---|
| 1. | B | 11. | A |
| 2. | C | 12. | D |
| 3. | D | 13. | B |
| 4. | C | 14. | C |
| 5. | D | 15. | B |
| 6. | B | 16. | A |
| 7. | E | 17. | C |
| 8. | D | 18. | B |
| 9. | C | 19. | C |
| 10. | A | 20. | B |

MICROBIOLOGY

<i>Microbiology Module (125 items)</i>	
<i>General Principles</i>	65%–70%
Biochemistry, Molecular Biology, Genetics	5%–10%
Tissue Response to Disease	1%–5%
Pharmacodynamic/Pharmacokinetic Processes	1%–5%
Microbial Biology and Infection	50%–55%
Microbial classification and its basis	1%–5%
Bacteria and bacterial diseases	25%–30%
Viruses and viral diseases	20%–25%
Fungi and fungal infections	1%–5%
Parasites and parasitic diseases	1%–5%
Principles of sterilization and pure culture technique	1%–5%
Immune Responses	1%–5%
 <i>Organ Systems</i>	 10%–15%
Hematopoietic & lymphoreticular	1%–4%
Central & peripheral nervous	1%–4%
Skin & related connective tissue	1%–4%
Musculoskeletal	1%–4%
Respiratory	1%–4%
Cardiovascular	1%–4%
Gastrointestinal	1%–4%
Renal/urinary	1%–4%
Reproductive	1%–4%
 <i>Immunology Module (25 items)</i>	
Immunologic Processes	12%–15%
Immunologic Diseases	8%–10%

1. A 45-year-old woman comes to the physician because of progressive facial swelling and pain during the past week. She has a 10-year history of poorly controlled type 1 diabetes mellitus. Physical examination shows ecchymoses over the left orbital and periorbital regions with proptosis. There is a necrotic lesion with a black eschar in the left naris. Findings on microscopic examination of material from the lesion include broad, irregularly shaped, nonseptate hyphae with branches at right angles. Which of the following is the most likely cause of the nasal lesion?

 - (A) *Histoplasma capsulatum*
 - (B) *Rhizopus oryzae*
 - (C) *Sporothrix schenckii*
 - (D) *Torulopsis glabrata*
 - (E) *Trichophyton rubrum*
2. A 21-year-old woman who is a college student is brought to the emergency department 2 hours after the onset of fever, chills, severe headache, and confusion. Her temperature is 39°C (102.2°F), respirations are 16/min, and blood pressure is 100/60 mm Hg. Physical examination shows numerous petechial lesions over the upper and lower extremities. There is resistance to neck flexion. Analysis of cerebrospinal fluid shows numerous leukocytes and gram-negative diplococci. Administration of which of the following vaccines is most likely to have prevented this patient's condition?

 - (A) *Haemophilus influenzae* type b vaccine
 - (B) Meningococcal conjugate vaccine, 4-valent
 - (C) Pneumococcal conjugate vaccine, 7-valent
 - (D) Pneumococcal polysaccharide vaccine, 23-valent
 - (E) Varicella vaccine

3. A sexually active 37-year-old woman comes to the physician because of a 2-day history of pain in the area of her genitals. Pelvic examination shows shallow, small, extremely tender ulcers with red bases in the vulvar and vaginal regions. A Tzanck smear shows the presence of multinucleated giant cells. Which of the following infectious agents is the most likely cause of these findings?
- (A) *Candida albicans*
 - (B) *Chlamydia trachomatis*
 - (C) Herpes simplex virus
 - (D) *Treponema pallidum*
 - (E) *Trichomonas vaginalis*
4. During an experimental study, an investigator develops a new member of the class of non-nucleoside reverse transcriptase inhibitors. This new drug most likely inhibits HIV infection through which of the following mechanisms?
- (A) Binding to reverse transcriptase
 - (B) Binding to RNase H
 - (C) Blockade of integration
 - (D) Incorporation into viral DNA
 - (E) Phosphorylation of nucleoside triphosphates
5. A 35-year-old woman delivers a newborn who develops meningitis. The mother has a streptococcus isolated from her vagina. The organism agglutinates with antiserum directed against type B surface carbohydrate. The virulence of this organism is related to a bacterial constituent that interferes with which of the following host phagocyte functions?
- (A) Aggregation
 - (B) Chemotaxis
 - (C) Ingestion
 - (D) Intracellular killing
 - (E) Pseudopod formation
6. A 33-year-old woman contracts malaria while on a 3-month business trip to a Central American country. She is treated with a full course of chloroquine and recovers uneventfully. Four months after returning to the USA, she has another febrile illness that resembles malaria. A peripheral blood smear shows ring forms in her erythrocytes. Which of the following species of *Plasmodium* is most likely to have caused the second febrile illness?
- (A) *P. falciparum*
 - (B) *P. knowlesi*
 - (C) *P. malariae*
 - (D) *P. vivax*
7. Three weeks after traveling to California to study desert flowers, a 33-year-old man develops fever, chest pain, and muscle soreness. Two days later, red, tender nodules appear on the shins, and the right ankle is tender and painful. An x-ray of the chest shows a left pleural effusion. Which of the following is the most likely diagnosis?
- (A) Blastomycosis
 - (B) Coccidioidomycosis
 - (C) Histoplasmosis
 - (D) *Mycobacterium marinum* infection
 - (E) *Mycoplasma pneumoniae* infection
8. At a banquet, the menu includes fried chicken, home-fried potatoes, peas, chocolate eclairs, and coffee. Within 2 hours, most of the diners become violently ill, with nausea, vomiting, abdominal pain, and diarrhea. Analysis of the contaminated food is most likely to yield large numbers of which of the following organisms?
- (A) *Enterococcus faecalis*
 - (B) *Escherichia coli*
 - (C) *Proteus mirabilis*
 - (D) *Salmonella typhimurium*
 - (E) *Staphylococcus aureus*
9. A 35-year-old woman is admitted to the hospital because of fever and dry cough for 3 days. An x-ray of the chest shows abnormal findings. Laboratory tests show cold agglutinating antibodies in serum. Results of routine cultures of blood and sputum are negative. Which of the following is the most likely pathogen?
- (A) Influenza virus
 - (B) *Mycobacterium tuberculosis*
 - (C) *Mycoplasma pneumoniae*
 - (D) *Staphylococcus aureus*
 - (E) *Streptococcus pneumoniae*
10. A mutation that causes the loss of the 3', 5' exonuclease activity of DNA-dependent DNA polymerase is most likely to also cause *Escherichia coli* to have problems with which cellular process?
- (A) Replacing misincorporated bases
 - (B) Segregating sister chromosomes
 - (C) Supercoiling of DNA
 - (D) Synthesizing an RNA primer
 - (E) Transferring DNA strands during conjugation

11. A 69-year-old woman comes to the emergency department because of a 2-day history of increasingly severe fever and back pain; she also has a burning sensation with urination, and there is an aromatic smell to the urine. She has had three urinary tract infections treated with ciprofloxacin during the past year. Her temperature is 39.1°C (102.3°F). Physical examination shows right flank tenderness. Laboratory studies show:

Leukocyte count	15,500/mm ³
Urine	
pH	9
Protein	trace
WBC	numerous
Bacteria	>100,000 colonies/mL

A urine culture grows a urease-positive organism that displays swarming motility on nonselective agar. Which of the following is the most likely causal organism?

- (A) *Enterococcus faecalis*
- (B) *Escherichia coli*
- (C) *Klebsiella pneumoniae*
- (D) *Proteus mirabilis*
- (E) *Staphylococcus saprophyticus*

12. During an experiment, an investigator gently abrades the skin from the flank of a mouse, creating a 1 × 2-cm skin window. A glass coverslip is then placed over the area so that cells attracted to the site attach to the coverslip for assessment. Two hours later, an extravasation of cells from the vasculature is noted on the coverslip. Which of the following complement components is the direct cause of the enhanced vascular permeability and chemoattraction in the abraded skin area in this experiment?

- (A) C1q
- (B) C4b
- (C) C5a
- (D) C7
- (E) C9

13. A 35-year-old man comes to the physician for a follow-up examination. He has had persistent left upper quadrant abdominal pain for 3 weeks despite therapy with omeprazole. Upper esophagogastroduodenoscopy shows an active duodenal ulcer. Tests of gastric and duodenal biopsy specimens for urease are positive. Which of the following is the most likely causal organism?

- (A) *Campylobacter jejuni*
- (B) *Clostridium difficile*
- (C) *Helicobacter pylori*
- (D) *Proteus vulgaris*
- (E) *Salmonella typhi*

14. A 2-year-old boy is diagnosed with staphylococcal scalded skin syndrome. In vitro studies show the causal organism to be resistant to penicillin. Which of the following mechanisms of action is most likely involved in this resistance?

- (A) Active efflux of the antibiotic from the bacteria
- (B) Decreased uptake of the antibiotic into the bacteria
- (C) Mutation of the 30S ribosomal subunit
- (D) Mutation of the 50S ribosomal subunit
- (E) Production of β-lactamase by the bacteria

15. A 3-year-old girl is brought to the emergency department by her father because of a persistent cough for 2 weeks. She sometimes vomits following a paroxysm of coughing. While she is not coughing, she appears well. She has not yet received any routine childhood vaccinations. Her temperature is 37°C (98.6°F). Physical examination shows petechiae over the sclera and face. Which of the following is the most likely diagnosis?

- (A) Diphtheria
- (B) Influenza
- (C) Pertussis
- (D) Plague
- (E) Tularemia

16. An investigator injects an experimental animal with a newly discovered bacterial strain to evaluate T-lymphocyte activation. It is found that bacterial engulfment by macrophages results in the presentation of bacterial-derived peptide ligands to CD4+ T lymphocytes. Which of the following cell-surface molecules on the macrophage is most directly involved in the presentation of the processed peptides?

- (A) CD28
- (B) Class II MHC
- (C) Fcε receptor
- (D) Interleukin-2 (IL-2) receptor
- (E) Membrane immunoglobulin

17. An investigator conducts an experiment on *Clostridium perfringens* and then sterilizes the culture dishes by autoclaving. This method of sterilization is most appropriate because it ensures that which of the following bacterial structures are inactivated?

- (A) Adhesion factors
- (B) Endotoxins
- (C) Fimbriae
- (D) Pili
- (E) Spores

18. A 52-year-old woman living in Maryland comes to the physician because of a 1-week history of low-grade fever, fatigue, and a red rash over the skin behind her left knee. She is an avid hiker. Her temperature is 38°C (100.4°F). Physical examination shows an 8-cm, warm, nontender, erythematous lesion with partial central clearing over the skin of the left popliteal area. Which of the following is the most likely causal organism?

- (A) *Borrelia burgdorferi*
- (B) *Ehrlichia chaffeensis*
- (C) *Francisella tularensis*
- (D) *Rickettsia rickettsii*
- (E) *Streptobacillus moniliformis*

19. An 8-month-old girl is brought to the emergency department because of a 1-day history of rapid breathing. Her temperature is 38.4°C (101.1°F), pulse is 160/min, respirations are 60/min, and blood pressure is 100/68 mm Hg. Bilateral expiratory wheezing and crackles are heard on auscultation. A chest x-ray shows areas of atelectasis and hyperinflation. Which of the following is the most likely causal virus?

- (A) Measles virus
- (B) Respiratory syncytial virus
- (C) Rhinovirus
- (D) Rotavirus
- (E) Varicella-zoster virus

20. A 45-year-old man comes to the physician because of fever and night sweats for 8 days. He has Crohn disease treated with infliximab. His temperature is 39°C (102.2°F). Physical examination shows diffuse cervical lymphadenopathy. A biopsy specimen of the nodes shows caseating granulomas. No organisms are identified on Gram stain. Which of the following is the most likely causal organism?

- (A) *Aspergillus niger*
- (B) *Brucella abortus*
- (C) *Francisella tularensis*
- (D) *Mycobacterium tuberculosis*
- (E) *Treponema pallidum*

Answer Form for Microbiology Sample Questions

(Questions 1-20)

- | | |
|-----------|-----------|
| 1. _____ | 11. _____ |
| 2. _____ | 12. _____ |
| 3. _____ | 13. _____ |
| 4. _____ | 14. _____ |
| 5. _____ | 15. _____ |
| 6. _____ | 16. _____ |
| 7. _____ | 17. _____ |
| 8. _____ | 18. _____ |
| 9. _____ | 19. _____ |
| 10. _____ | 20. _____ |

Answer Key for Microbiology Sample Questions

(Questions 1-20)

- | | | | |
|-----|---|-----|---|
| 1. | B | 11. | D |
| 2. | B | 12. | C |
| 3. | C | 13. | C |
| 4. | A | 14. | E |
| 5. | C | 15. | C |
| 6. | D | 16. | B |
| 7. | B | 17. | E |
| 8. | E | 18. | A |
| 9. | C | 19. | B |
| 10. | A | 20. | D |

NEUROSCIENCE

Biology of cells (signal transduction, muscle cells)	1%–5%
Central and peripheral nervous system	95%–99%
Normal processes	65%–70%
Embryonic development	1%–5%
Organ structure and function	50%–55%
Spinal cord	5%–10%
Brain stem	5%–10%
Brain	5%–10%
Sensory systems	5%–10%
Motor systems	5%–10%
Autonomic nervous systems	1%–5%
Peripheral nerve	1%–5%
Cell/tissue structure and function	5%–10%
Repair, regeneration, and changes associated with stage of life	1%–5%
Abnormal processes	25%–30%
Infectious, inflammatory, immunologic disorders	1%–5%
Traumatic and mechanical disorders	1%–5%
Neoplastic disorders	1%–5%
Metabolic/regulatory disorders	1%–5%
Vascular disorders	1%–5%
Systemic disorders	1%–5%
Idiopathic disorders	1%–5%
Congenital/metabolic disorders	1%–5%
Degenerative disorders	1%–5%
Paroxysmal disorders	1%–5%
Disorders of the special senses	1%–5%
Principles of therapeutics	1%–5%

1. A 43-year-old man sustains a wound to the lateral neck. This results in weakness of elevation and retraction of the shoulder on the ipsilateral side and difficulty turning the head up and toward the contralateral side. No sensory changes are present. Which of the following nerves most likely has been injured?

(A) Axillary
(B) Lateral cord of the brachial plexus
(C) Phrenic
(D) Spinal accessory
(E) Suprascapular
3. Drug X applied to a nerve axon decreases the duration of the action potential without affecting the resting potential or peak amplitude of the action potential. Which of the following is the most likely mechanism of action of Drug X?

(A) Block of voltage-dependent Na⁺ permeability
(B) Decrease in the rate of Na⁺ inactivation
(C) Decrease in voltage-dependent Na⁺ permeability
(D) Increase in the rate of voltage-dependent changes in K⁺ permeability
(E) Inhibition of the Na⁺–K⁺ pump
2. An investigator is studying normal sleep patterns in healthy men and women. Saccadic motions of the eyes are seen approximately 90 minutes after the volunteers fall asleep. Which of the following is most likely to be observed in the volunteers during this period of saccadic eye movements?

(A) Difficulty awakening
(B) An EEG pattern resembling that of the waking state
(C) Hyperactive muscle tone
(D) Increased movements
(E) Irregular respiratory rhythm
4. A 65-year-old man has loss of pain and temperature sensation on the right side of the face and from the neck down on the left. Examination shows partial paralysis of the soft palate, larynx, and pharynx, and ataxia, all on the right. The most likely cause of these findings is thrombosis to which of the following arteries?

(A) Basilar
(B) Right posterior inferior cerebellar
(C) Left posterior inferior cerebellar
(D) Right superior cerebellar
(E) Left superior cerebellar

5. A 45-year-old man has a progressively severe headache. Funduscopic examination discloses blurred margins and bulging of the optic discs. The retinal veins are engorged and show no pulsatile flow. Which of the following is the mechanism most likely to explain these findings?
- (A) Acute occlusion of the retinal artery
 - (B) Demyelination of the optic nerve
 - (C) Increased intracranial pressure
 - (D) Inflammation of the anterior chamber
 - (E) Inflammation of the optic nerve
6. A 4-month-old boy is brought to the physician by his mother for a well-child examination. He is at the 98th percentile for head circumference. Physical examination shows dilation of the scalp veins and spasticity of the lower extremities. The physician suspects excessive cerebrospinal fluid accumulation in the ventricular system of the brain. The source of this fluid is most likely which of the following?
- (A) Choroid plexus
 - (B) Dura mater
 - (C) Pia mater
 - (D) Roof of the third ventricle
7. A 68-year-old woman is brought to the physician by her husband because of strange behavior. The previous evening, she had gotten up suddenly from the dinner table and started to undress in front of guests. Further questioning discloses a 1-year history of a progressive change in behavior. She writes everything down on a notepad; otherwise, she forgets. She cannot remember the names of her four grandchildren or the date of her wedding anniversary. These symptoms are most likely associated with a deficit in which of the following?
- (A) Acetylcholine
 - (B) Dopamine
 - (C) Glucose 6-phosphate dehydrogenase
 - (D) Insulin
 - (E) Serotonin
8. A 50-year-old man has had gradually progressive hand weakness. He has atrophy of the forearm muscles, fasciculations of the muscles of the chest and arms, hyperreflexia of the lower extremities, and extensor plantar reflexes. Sensation is not impaired. Which of the following is the most likely diagnosis?
- (A) Amyotrophic lateral sclerosis
 - (B) Dementia, Alzheimer type
 - (C) Guillain-Barré syndrome
 - (D) Multiple cerebral infarcts
 - (E) Multiple sclerosis
9. An 8-year-old boy is brought to the physician by his mother because he is not paying attention in class. His mother says that his teacher has described his in-school behavior as “frequently stopping what he is doing and then blinking and making chewing movements.” His mother has noticed that he sometimes “stares off into space” and seems to be daydreaming. Physical examination shows no abnormalities. An EEG during one of the episodes shows generalized spike-and-wave bursts at 3 Hz per second. This patient most likely has which of the following types of seizures?
- (A) Absence
 - (B) Akinetic
 - (C) Complex partial
 - (D) Generalized tonic-clonic
 - (E) Myoclonic
10. A previously healthy 18-year-old man is brought to the emergency department because of fever, a poorly localized headache, and a stiff neck for 12 hours. The symptoms were preceded by nasal congestion, muscle aches, and chills 3 days ago. His temperature is 38.7°C (101.6°F). Physical examination shows nuchal rigidity and photophobia. There is no papilledema. Neurologic examination shows no focal findings. Which of the following is the most likely diagnosis?
- (A) Acute meningitis
 - (B) Classic migraine
 - (C) Cluster headache
 - (D) Idiopathic intracranial hypertension
 - (E) Subarachnoid hemorrhage
 - (F) Temporal arteritis
 - (G) Tension-type headache
11. A 36-year-old woman comes to the physician because of a 10-month history of difficulty falling asleep due to a crawling sensation in her legs. She has to get up several times during the night to relieve the feeling. The symptoms started shortly after she delivered her son 1 year ago. She says her husband complains because she has become a “jumpy” sleeper, and her movements sometimes wake him up. Physical examination shows no abnormalities. Which of the following is the most likely diagnosis?
- (A) Amyotrophic lateral sclerosis
 - (B) Multiple sclerosis
 - (C) REM sleep behavior disorder
 - (D) Restless legs syndrome
 - (E) Sleep myoclonus

12. A 53-year-old woman dies 4 days after an automobile collision. She sustained multiple injuries including a femoral fracture. Widespread petechiae are found in the cerebral white matter at autopsy. Which of the following is the most likely cause of these findings?
- (A) Acute respiratory distress syndrome
 - (B) Contrecoup injury
 - (C) Fat embolization
 - (D) Septicemia
 - (E) Subdural hematoma
13. A 23-year-old woman with chronic hepatic disease is brought to the physician because of a 6-month history of progressive behavioral and personality changes, difficulty walking, clumsiness of her arms and legs, and slurred speech. Physical examination shows facial dystonia and dysarthria. There is intention tremor, rigidity, and ataxia of all extremities. Slit-lamp examination shows a brownish ring around the cornea of both eyes. Which of the following abnormalities in plasma is most likely in this patient?
- (A) Decreased calcium concentration
 - (B) Decreased ceruloplasmin concentration
 - (C) Decreased transferrin concentration
 - (D) Increased ammonium concentration
 - (E) Increased ketones
 - (F) Increased lactate concentration
14. A new drug is developed that prevents the demyelination occurring in the progress of multiple sclerosis. The drug protects the cells responsible for the synthesis and maintenance of myelin in the central nervous system. These cells are most likely which of the following?
- (A) Astrocyte
 - (B) Ependymal cell
 - (C) Microglial cell
 - (D) Oligodendrocyte
 - (E) Schwann cell
15. A 47-year-old man with Down syndrome is brought to the physician by his sister because of an 8-month history of regression in his abilities. The sister describes a gradual decline in his language skills and progressive fearfulness. The patient no longer remembers songs that he has known for years, and he does not wish to participate in family activities anymore. Pathologic examination of the brain would most likely show which of the following in this patient?
- (A) Deposits of long-chain fatty acids
 - (B) Intracellular arylsulfatase A
 - (C) Lewy bodies and nigral atrophy
 - (D) Neuronal plaques and tangles
 - (E) Perivenular inflammatory cells
16. A 29-year-old man who emigrated from Scotland 3 years ago is brought to the emergency department because of severe shortness of breath for 2 hours. He has a debilitating condition that began 2 years ago with an odd sticky feeling of his skin, but physical examination at that time showed no abnormalities. His condition has progressed to include severe major depressive disorder, dementia, unsteady gait, difficulty walking, and impaired coordination. He now is confined to a wheelchair and has severe dementia and the inability to speak. There is no family history of a similar condition. On arrival, his respirations are 24/min, and he dies shortly thereafter. At autopsy, examination of the brain shows a spongiform encephalopathy. Which of the following is the most likely diagnosis?
- (A) Dementia, Alzheimer type
 - (B) Frontotemporal dementia
 - (C) Parkinson disease
 - (D) Pick disease
 - (E) Variant Creutzfeldt-Jakob disease
17. A 52-year-old woman comes to the physician because of gradual loss of feeling in her feet during the past 6 months. She is a portrait painter. She has a 23-year history of hypertension and a 20-year history of type 2 diabetes mellitus. Menopause occurred 1 year ago. She has smoked 2 packs of cigarettes daily for 30 years. She took an oral contraceptive for 20 years. Current medications include hormone replacement therapy, diuretics, and an oral hypoglycemic agent. Her blood pressure is 135/85 mm Hg. Sensation to pinprick is decreased over both feet. Which of the following is the strongest predisposing risk factor of this new finding?
- (A) Hypertension
 - (B) Long-term exposure to paint fumes
 - (C) Long-term use of exogenous hormones
 - (D) Long-term use of tobacco
 - (E) Type 2 diabetes mellitus
18. A 49-year-old woman comes to the physician because of a 3-month history of waking at night because of pain and numbness of her right hand. She reports that shaking her hand decreases the severity of the pain. She has been cutting hair at a beauty salon 6 days weekly for 35 years. Examination of the right hand shows tenderness with palpation and distal tingling on percussion of the volar wrist. Prolonged forcible palmar flexion of the right wrist produces tingling. Which of the following is the most likely diagnosis?
- (A) Carpal tunnel syndrome
 - (B) Early rheumatoid arthritis
 - (C) Osteoarthritis
 - (D) Stress fracture
 - (E) Tendinitis

19. A 65-year-old woman has had double vision, difficulty keeping her eyes open, and diffuse weakness for the past several months. She has bilateral ptosis that worsens with sustained upward gaze, limited horizontal and vertical movements in both eyes, and nasal speech. Her symptoms and signs improve transiently following intravenous injection of edrophonium. An abnormality is most likely to be found in which of the following structures?
- (A) Anterior horn cell
 - (B) Motor cortex
 - (C) Neuromuscular junction
 - (D) Peripheral nerve
 - (E) Skeletal muscle
20. A 21-year-old woman comes to the physician 2 weeks after being involved in a motor vehicle collision that occurred when she fell asleep while driving. She says that during the past 2 years she has had several incidents of falling asleep at inappropriate times, including while walking. She also reports intermittent loss of muscle tone while awake and occasional sleep paralysis. She does not snore. Physical examination shows no abnormalities. Polysomnography shows a sleep latency of less than 5 minutes and four sleep-onset REM periods. Which of the following is the most likely diagnosis?
- (A) Chronic insomnia
 - (B) Narcolepsy
 - (C) Restless legs syndrome
 - (D) Sleep apnea
 - (E) Sleep bruxism

Answer Form for Neuroscience Sample Questions

(Questions 1-20)

- | | |
|-----------|-----------|
| 1. _____ | 11. _____ |
| 2. _____ | 12. _____ |
| 3. _____ | 13. _____ |
| 4. _____ | 14. _____ |
| 5. _____ | 15. _____ |
| 6. _____ | 16. _____ |
| 7. _____ | 17. _____ |
| 8. _____ | 18. _____ |
| 9. _____ | 19. _____ |
| 10. _____ | 20. _____ |

Answer Key for Neuroscience Sample Questions

(Questions 1-20)

- | | | | |
|-----|---|-----|---|
| 1. | D | 11. | D |
| 2. | B | 12. | C |
| 3. | D | 13. | B |
| 4. | B | 14. | D |
| 5. | C | 15. | D |
| 6. | A | 16. | E |
| 7. | A | 17. | E |
| 8. | A | 18. | A |
| 9. | A | 19. | C |
| 10. | A | 20. | B |

PATHOLOGY

<i>General Principles</i>	35%–40%
Cell Biology	1%–5%
Human Development and Genetics	1%–5%
Biology of Tissue Response	10%–15%
Multisystem Processes	5%–10%
Microbial Biology and Infection	1%–5%
Immune Responses	5%–10%
<i>Organ Systems</i>	60%–65%
Hematopoietic & lymphoreticular	5%–10%
Central & peripheral nervous	5%–10%
Skin & related connective tissue	5%–10%
Musculoskeletal	1%–5%
Respiratory	1%–5%
Cardiovascular	5%–10%
Gastrointestinal	5%–10%
Renal/urinary	5%–10%
Reproductive	5%–10%
Endocrine	1%–5%

-
1. A 16-year-old boy is undergoing evaluation for jaundice. Laboratory studies show normal hepatic enzyme activities, a negative direct antiglobulin (Coombs) test, increased mean corpuscular hemoglobin concentration, and increased osmotic fragility of erythrocytes. Which of the following types of erythrocyte is most likely to be seen on a peripheral blood smear?

 - (A) Ovalocyte
 - (B) Schistocyte
 - (C) Spherocyte
 - (D) Target cell
 - (E) Teardrop cell
 2. A 34-year-old woman is brought to the emergency department by her husband because of confusion for 2 hours. She is unconscious on arrival. Her husband says that she has a 1-year history of episodes of nervousness, light-headedness, and dizziness that resolve after she eats a meal. Physical examination shows no other abnormalities. Her serum glucose concentration is 25 mg/dL. After an intravenous infusion of 0.9% saline and glucose, she regains consciousness. Which of the following is the most likely diagnosis?

 - (A) Cushing syndrome
 - (B) Insulinoma
 - (C) Multiple endocrine neoplasia syndrome
 - (D) Pancreatic gastrinoma
 - (E) Pheochromocytoma
 3. A 60-year-old man comes to the physician because of a cough for 2 months. He says that he has noticed changes in his face during the past 3 months. He has smoked 2 packs of cigarettes daily for 30 years. His temperature is 37°C (98.6°F), pulse is 72/min, respirations are 19/min, and blood pressure is 160/95 mm Hg. Physical examination shows a round face, central obesity, excess fat over the posterior neck and back, and abdominal striae. His serum calcium concentration is 9 mg/dL. Urine dipstick of a clean-catch midstream specimen shows 3+ glucose. A chest x-ray shows a 3-cm mass in the left upper lobe with enlargement of hilar nodes. A biopsy specimen of the mass shows small cell carcinoma. Further serum studies are most likely to show an increased concentration of which of the following proteins?

 - (A) Adrenocorticotropic hormone
 - (B) Epidermal growth factor
 - (C) IgM
 - (D) Parathyroid hormone-related protein
 - (E) Serotonin

4. A 45-year-old man with chronic pancreatitis has a 9-kg (20-lb) weight loss and diarrhea. Analysis of a 24-hour stool sample shows 28 g of fat. A deficiency of which of the following enzymes is the most likely cause?
- Amylase
 - Carboxypeptidase
 - Lactase
 - Lipase
 - Lipoprotein lipase
5. A 70-year-old man comes to the physician because of a 2-year history of shortness of breath and progressive chest pain. He worked as a carpenter installing insulation from the ages of 21 to 31 years. Physical examination shows absent breath sounds and dullness to percussion over the right lung base. A chest x-ray shows thickened pleura on the right side and a medium-sized pleural effusion. Pleural fluid studies show a protein concentration greater than 3 g/dL (N=1–2). A pleural biopsy specimen shows spindle cells. Which of the following is the most likely diagnosis?
- Emphysema
 - Lung abscess
 - Mesothelioma
 - Small cell carcinoma of the lung
 - Viral pneumonia
6. A previously healthy 28-year-old man dies in a motor vehicle collision. At autopsy, the kidneys are enlarged bilaterally, and each weighs 3 kg. The external surface of the kidneys appears to be a mass of cysts. Microscopic examination of the kidneys shows intact nephrons interspersed between the cysts. The most likely cause of these changes in the kidneys involves which of the following modes of inheritance?
- Autosomal dominant
 - Autosomal recessive
 - Chromosome 22q11.2 deletion
 - Mitochondrial
 - X-linked
7. An autopsy of a 24-year-old woman shows pleuritis, membranous thickening of glomerular capillary walls, concentric rings of collagen around splenic arterioles, and excrescences on the underside of the mitral valve. Analysis of blood is most likely to show which of the following?
- Antinuclear antibody
 - Increased C3 concentration
 - Lymphocytosis
 - Monoclonal gammopathy
 - Positive bacterial culture
8. At autopsy, the heart of a 30-year-old man weighs 550 g. The left ventricle is dilated and hypertrophied. The aortic root is markedly dilated, and the aortic valve cusps are intact. The external iliac arteries contain irregular, focal cystic areas within the media with pools of mucopolysaccharide and fraying fragmentation of the elastica. Which of the following is the most likely diagnosis?
- Ankylosing spondylitis
 - Cardiovascular syphilis
 - Marfan syndrome
 - Osteogenesis imperfecta, type II (recessive)
 - Systemic lupus erythematosus
9. A 10-year-old boy is brought to the emergency department 15 minutes after he sustained abdominal injuries in a motor vehicle collision. Physical examination shows massive ecchymoses over the trunk and abdomen. A CT scan shows internal bleeding. The patient undergoes operative removal of a portion of the lower left lobe of the lung, the left lobe of the liver, half of the left kidney, half of the spleen, and a 2-foot section of the small intestine. Assuming survival of the acute trauma, which of the following organs is likely to have the most complete regeneration in this patient?
- Kidney
 - Liver
 - Lung
 - Small intestine
 - Spleen
10. A previously healthy 2-year-old boy is brought to the emergency department because of bloody stools for 2 days. His vital signs are within normal limits. Abdominal examination shows no abnormalities. Laboratory studies show:
- | | |
|-----------------|-------------------------|
| Hemoglobin | 11 g/dL |
| Hematocrit | 37% |
| Leukocyte count | 9500/mm ³ |
| Platelet count | 250,000/mm ³ |
- Test of the stool for occult blood is positive. During an emergency laparotomy, a 3 × 2-cm protrusion is found on the antimesenteric border of the small intestine approximately 50 cm proximal to the ileocecal valve. Which of the following is the most likely cause of this patient's condition?
- Carcinoid tumor
 - Ectopic adrenal gland
 - Meckel diverticulum
 - Retrocecal appendix
 - Umbilical hernia

11. A 50-year-old man comes to the physician because of progressive fatigue and darkening of his skin during the past 2 years. He has not spent much time in the sun during this period. Physical examination shows slate-gray skin and hepatomegaly. Serum studies show:

Ferritin	500 ng/mL
Transferrin saturation	70% (N=20%–60%)
AST	41 U/L
ALT	45 U/L

A liver biopsy specimen stained with Prussian blue is positive. Which of the following best describes the altered function of mutated HFE gene product in this patient?

- (A) Decreased lysozyme synthesis
 - (B) Decreased NADPH production
 - (C) Decreased oxidase activity
 - (D) Increased fatty acid absorption
 - (E) Increased iron absorption
12. A 69-year-old woman is brought to the emergency department because of progressive difficulty with her vision during the past day. She also has a 3-month history of headache and scalp tenderness. She says, "This morning I had a blind spot in my left eye, and it just grew bigger as the day went on." Her vital signs are within normal limits. Ophthalmologic examination shows visual acuity of 20/100 in the left eye and 20/40 in the right eye. Physical examination shows no other abnormalities. Laboratory studies show an erythrocyte sedimentation rate of 129 mm/h. Which of the following is the most likely diagnosis?
- (A) Acute occipital infarction
 - (B) Glaucoma
 - (C) Left carotid dissection
 - (D) Systemic lupus erythematosus
 - (E) Temporal arteritis
13. A 30-year-old woman comes to the physician because of a 2-month history of unsteady gait and numbness of both legs. Eight years ago, she underwent resection of the terminal ileum because of severe Crohn disease. Physical examination shows mild spastic weakness. Sensation to pinprick, vibration, and fine touch is decreased in the upper and lower extremities. A deficiency of which of the following is the most likely underlying cause of these findings?
- (A) Folic acid
 - (B) Iron
 - (C) Protein
 - (D) Vitamin B₁ (thiamine)
 - (E) Vitamin B₁₂ (cobalamin)

14. A 10-month-old girl is brought to the physician by her father because she does not seem to be gaining weight despite an increased appetite. He says that she passes 8 to 10 stools daily. She has no history of major medical illness, but during the past winter she had several infections of the ear and respiratory tract that were treated with antibiotics. She appears malnourished but is in no apparent distress. She is at the 5th percentile for length and weight. Diffuse crackles are heard over the lower lung fields on auscultation. Her sweat chloride concentration is 69 mmol/L. Which of the following is the most likely underlying cause of these findings?

- (A) Abnormal cystic fibrosis transmembrane conductance regulator gene function
 - (B) Acid phosphatase deficiency
 - (C) Atypical conjugation of arylsulfatase A, B, and C
 - (D) α -1-Fucosidase deficiency
 - (E) Impaired production of phosphatidylcholine (lecithins)
15. The chairman of a large pathology department is planning for the personnel that he will need in the future. He is trying to decide whether his department will have more need for a dermatopathologist or a cytopathologist. He decides against the cytopathologist because he expects the number of Pap smears to fall off dramatically in the future. The development of which of the following is the most likely reason for this expected decrease in the number of Pap smears?
- (A) Highly effective oral drugs that prevent dysplasia of the uterine cervix
 - (B) Operative guidelines requiring the amputation of the cervix for mild squamous dysplasia
 - (C) Three-dimensional conformal radiation treatment
 - (D) A vaccine against high-risk human papillomaviruses
 - (E) Vaginal suppositories that markedly reduce the number of bacteria in the vagina

16. A 22-year-old woman comes to the physician because of a 1-day history of fever and right flank pain. Her temperature is 39°C (102.2°F). Physical examination shows right flank tenderness. Urinalysis shows bacteria, numerous WBC/hpf, and WBC casts. Complete blood count shows leukocytosis. Which of the following is the most likely diagnosis?
- (A) Cervicitis
 - (B) Cystitis
 - (C) Pyelonephritis
 - (D) Urethritis
 - (E) Vaginitis
17. A previously healthy 30-year-old woman comes to the physician for a follow-up visit after a chest x-ray shows bilateral hilar adenopathy and a calcified 1-cm nodule in the periphery of the right lower lobe. Physical examination shows no abnormalities. Her serum calcium concentration is 11 mg/dL. Pulmonary function test results are within normal limits. Bronchoscopy with bronchoalveolar lavage yields 40% lymphocytes and 60% macrophages, with a CD4:CD8 T-lymphocyte ratio of 10:1. A bronchial biopsy specimen shows a nonnecrotizing granuloma. Specially stained sections of a bronchial biopsy specimen show no acid-fast bacilli or fungi. Cultures of lung tissue grow no organisms. Which of the following is the most likely diagnosis?
- (A) Coccidioidomycosis
 - (B) Hypersensitivity pneumonitis
 - (C) Sarcoidosis
 - (D) Silicosis
 - (E) Tuberculosis
 - (F) Wegener granulomatosis
18. A 3-year-old girl is brought to the emergency department 30 minutes after she tripped and fell. Physical examination shows blue sclera and edema and tenderness over the right proximal lower extremity. X-rays show a fracture of the right femur, as well as several fractures of varying ages of the left clavicle, right humerus, and right fibula. Which of the following is the most likely diagnosis?
- (A) Achondroplasia
 - (B) Ehlers-Danlos syndrome
 - (C) Hurler syndrome
 - (D) Marfan syndrome
 - (E) Osteogenesis imperfecta
19. A 50-year-old man with type 2 diabetes mellitus has a 1-week history of swelling and a feeling “like electric shocks” in his right wrist and hand. He is a computer programmer, and the shock-like feeling is worse with activity and at the end of the day. There is atrophy of the right thenar eminence. With the hand hyperextended, pain radiates into the fingers when the examiner taps the flexor surface of the distal wrist. Which of the following nerves is most likely compressed in this patient?
- (A) Deep radial
 - (B) Median
 - (C) Musculocutaneous
 - (D) Radial ulnar
 - (E) Superficial radial
20. A 3-year-old boy is brought to the physician because of a 2-day history of fever and an itchy rash. The rash began on his face and then spread to his trunk, arms, and legs. Several children at his day-care center have had similar symptoms. His temperature is 38.9°C (102°F), pulse is 100/min, respirations are 20/min, and blood pressure is 110/60 mm Hg. Physical examination shows multiple red papules and vesicles over the face, trunk, and upper and lower extremities. Some vesicles contain clear fluid, whereas others are crusted. Which of the following is the most likely causal virus?
- (A) Cytomegalovirus
 - (B) Epstein-Barr virus
 - (C) Herpes simplex virus 2
 - (D) Human papillomavirus
 - (E) Varicella-zoster virus

Answer Form for Pathology Sample Questions

(Questions 1-20)

- | | |
|-----------|-----------|
| 1. _____ | 11. _____ |
| 2. _____ | 12. _____ |
| 3. _____ | 13. _____ |
| 4. _____ | 14. _____ |
| 5. _____ | 15. _____ |
| 6. _____ | 16. _____ |
| 7. _____ | 17. _____ |
| 8. _____ | 18. _____ |
| 9. _____ | 19. _____ |
| 10. _____ | 20. _____ |

Answer Key for Pathology Sample Questions

(Questions 1-20)

- | | | | |
|-----|---|-----|---|
| 1. | C | 11. | E |
| 2. | B | 12. | E |
| 3. | A | 13. | E |
| 4. | D | 14. | A |
| 5. | C | 15. | D |
| 6. | A | 16. | C |
| 7. | A | 17. | C |
| 8. | C | 18. | E |
| 9. | B | 19. | B |
| 10. | C | 20. | E |

PHARMACOLOGY

<i>General Principles</i>	40%–45%
Pharmacokinetics, Pharmacodynamics	5%–10%
Antimicrobial Drugs	10%–15%
Carcinogens, Environmental Insults, Antineoplastic/Immunosuppressant Drugs	5%–10%
<i>Organ Systems (including mechanism of action, therapy, adverse effect)</i>	55%–60%
Hematopoietic & lymphoreticular	5%–10%
Central & peripheral nervous	35%–40%
Anesthetics	1%–5%
Hypnotics	1%–5%
Psychopharmacologic agents	1%–5%
Anticonvulsants	1%–5%
Stimulants, amphetamines	1%–5%
Antiparkinsonian drugs	1%–5%
Botulinum toxin	1%–5%
Neuromuscular junction blocking agents	1%–5%
Antiglaucoma drugs	1%–5%
Drugs used to decrease intracranial pressure	1%–5%
Antimigraine agents	1%–5%
Drugs affecting autonomic nervous system	5%–10%
Skin & related connective tissue	1%–5%
Musculoskeletal	1%–5%
Respiratory	1%–5%
Cardiovascular	15%–20%
Gastrointestinal	1%–5%
Renal/urinary	5%–10%
Reproductive	1%–5%
Endocrine	1%–5%

-
1. Ten months after starting procainamide therapy for cardiac arrhythmias, a 56-year-old man develops arthritis and other symptoms consistent with drug-induced systemic lupus erythematosus. Results of a blood test are positive for antinuclear antibodies. This finding is consistent with which of the following genetic polymorphisms in drug metabolism?
 - (A) Debrisoquine 4-hydroxylase deficiency
 - (B) Erythrocyte catechol-*O*-methyltransferase deficiency
 - (C) Glucose 6-phosphate dehydrogenase deficiency
 - (D) Phenytoin hydroxylase deficiency
 - (E) Slow acetylator phenotype
 2. An 83-year-old man has a 2-month history of akinesia, rigidity, and tremor. He has been taking a drug for the past 7 years to control severe behavioral and psychiatric symptoms associated with dementia, Alzheimer type. This adverse effect is most likely mediated through which of the following?
 - (A) Anticholinergic effects
 - (B) Antidopaminergic effects
 - (C) Downregulation of γ -aminobutyric acid (GABA)
 - (D) Inhibition of norepinephrine reuptake
 - (E) Inhibition of serotonin reuptake
 - (F) Upregulation of GABA

3. A 23-year-old man with HIV infection has *Pneumocystis jirovecii* pneumonia. Therapy is started with trimethoprim-sulfamethoxazole, and his pneumonia resolves. The pharmacotherapy was effective because of inhibition of which of the following?
- (A) Cell wall synthesis
 - (B) Dihydrofolate reductase
 - (C) Incorporation of *p*-aminobenzoic acid
 - (D) Incorporation of sterol into membranes
 - (E) Topoisomerase II
4. A 62-year-old man comes to the physician because of burning pain and tenderness of his right great toe 1 day after heavy ethanol consumption. Physical examination shows erythema, swelling, warmth, and tenderness of the right great toe. After a 2-week course of nonsteroidal anti-inflammatory drug treatment, his symptoms decrease in severity but do not completely resolve. The serum concentration of which of the following is most likely increased in this patient?
- (A) Calcium
 - (B) Carotene
 - (C) Creatinine
 - (D) Iron
 - (E) Orotic acid
 - (F) Phosphate
 - (G) Uric acid
5. A 62-year-old man is being treated with cisplatin for small cell carcinoma of the lungs. The efficacy of cisplatin depends on interaction with which of the following?
- (A) DNA
 - (B) DNA polymerase
 - (C) Growth factor receptors
 - (D) Reverse transcriptase
 - (E) Ribosomes
6. An 18-year-old woman comes to the physician because of nausea, vomiting, and abdominal pain 1 hour after ingesting a glass of wine with dinner. Three days ago, she began antibiotic treatment for vaginitis after a wet mount preparation of vaginal discharge showed a motile protozoan. This patient most likely has been taking which of the following drugs?
- (A) Ceftriaxone
 - (B) Chloroquine
 - (C) Clindamycin
 - (D) Metronidazole
7. A 20-year-old woman comes to the emergency department after ingesting at least 30 tablets of an unknown drug. Initial physical examination shows no abnormalities. Thirty-six hours later, serum AST activity is 1500 U/L, and serum ALT activity is 2000 U/L. The drug this patient ingested is most likely which of the following?
- (A) Acetaminophen
 - (B) Aspirin
 - (C) Chlorpheniramine
 - (D) Ibuprofen
 - (E) Prednisone
8. A 42-year-old woman who is a chemist is brought to the emergency department because of a 1-hour history of severe abdominal cramps, nausea and vomiting, hypotension, bradycardia, sweating, and difficulty breathing due to bronchospasm and congestion. Exposure to which of the following is most likely?
- (A) Acrylamide
 - (B) Cyanogen bromide
 - (C) Isoflurophate (DFP)
 - (D) Phentolamine
 - (E) Propranolol
9. A 35-year-old woman is diagnosed with gastroesophageal reflux disease. Omeprazole is administered. Which of the following is the most likely mechanism of action of this drug?
- (A) Blockade of gastrin receptors
 - (B) Blockade of H₁ receptors
 - (C) Blockade of M₃ receptors
 - (D) Inhibition of H⁺-K⁺ ATPase activity
 - (E) Inhibition of synthesis of gastrin
10. In a 40-year-old man with hypertension, which of the following agents has the greatest potential to activate presynaptic autoreceptors, inhibit norepinephrine release, and decrease sympathetic outflow?
- (A) α₁-Adrenergic agonist
 - (B) α₂-Adrenergic agonist
 - (C) β₁/β₂-Adrenergic antagonist
 - (D) Angiotensin-converting enzyme inhibitor
 - (E) Calcium antagonist

11. A 35-year-old woman is brought to the emergency department because of an 18-hour history of severe pain, nausea, vomiting, diarrhea, and anxiety. She was discharged with a pain medication from the hospital 2 weeks ago after treatment of multiple injuries sustained in a motor vehicle collision. She took her last dose 36 hours ago. Her temperature is 36.6°C (97.8°F), pulse is 105/min, respirations are 24/min, and blood pressure is 160/85 mm Hg. Physical examination shows rhinorrhea and piloerection. Bowel sounds are normal. She rates the pain as an 8 on a 10-point scale. Which of the following is the most likely diagnosis?
- (A) Acute appendicitis
 (B) Caffeine withdrawal
 (C) Ethanol withdrawal
 (D) Gastric ulcers
 (E) Gastroenteritis
 (F) Oxycodone withdrawal
12. A 21-year-old woman comes to the physician for counseling prior to conception. She delivered a female newborn with anencephaly 1 year ago. The newborn died at the age of 4 days. She asks the physician if she can take any vitamins to decrease her risk for conceiving a fetus with anencephaly. It is most appropriate for the physician to recommend which of the following vitamins?
- (A) Biotin
 (B) Folic acid
 (C) Vitamin B₁ (thiamine)
 (D) Vitamin B₂ (riboflavin)
 (E) Vitamin B₆ (pyridoxine)
 (F) Vitamin B₁₂ (cyanocobalamin)
13. A 38-year-old man comes to the physician because of a 6-month history of occasional episodes of chest tightness, wheezing, and cough. The symptoms are often mild and resolve spontaneously. He has been otherwise healthy. His respirations are 13/min. The lungs are clear to auscultation. Cardiac examination and chest x-ray show no abnormalities. Which of the following agents is most appropriate to treat acute episodes in this patient?
- (A) Albuterol
 (B) Beclomethasone
 (C) Cromolyn
 (D) Ipratropium
 (E) Theophylline
14. A new drug, Drug X, relieves pain by interacting with a specific receptor in the body. Drug X binds irreversibly to this receptor, resulting in a long duration of action. Which of the following types of bonds is most likely formed between Drug X and its receptor?
- (A) Covalent
 (B) Hydrogen
 (C) Hydrophobic
 (D) Ionic
 (E) van der Waals
15. A 49-year-old man with hypertension comes to the physician for a follow-up examination. At his last visit 2 months ago, his serum total cholesterol concentration was 320 mg/dL. He then began a low-cholesterol diet. His blood pressure is 145/95 mm Hg. Physical examination shows no other abnormalities. Serum studies show a total cholesterol concentration of 310 mg/dL. Kidney and liver function test results are within normal limits. The most appropriate pharmacotherapy for this patient is a drug that has which of the following mechanisms of action?
- (A) Activates peroxisome proliferator-activated receptors
 (B) Decreases hepatic production of VLDL cholesterol
 (C) Forms insoluble complexes with bile acids in the gut
 (D) Impairs absorption of cholesterol in the small intestine brush border
 (E) Inhibits 3-HMG-CoA reductase
16. A 17-year-old girl is brought to the physician by her parents 30 minutes after having a generalized tonic-clonic seizure while playing in a soccer game. She currently takes no medications. Physical examination shows no abnormalities. After further testing including 24-hour continuous EEG monitoring, carbamazepine is prescribed. This patient's use of additional medications should be monitored because of which of the following changes in drug disposition after starting pharmacotherapy?
- (A) Decreased absorption in the intestine
 (B) Decreased distribution to the brain
 (C) Increased excretion by the kidneys
 (D) Increased metabolism by the liver
 (E) Increased recirculation in the bile

17. A 14-year-old boy is brought to the physician for examination prior to participating on his school's soccer team. Physical examination shows jaundice. Serum studies show a total bilirubin concentration of 2.5 mg/dL, ALT activity of 70 U/L, and ceruloplasmin concentration of 5 mg/dL (N=20–40). A slit-lamp examination shows the presence of brownish rings in the cornea, surrounding the iris. The most appropriate treatment at this time is a drug with which of the following mechanisms of action?
- (A) Decreases serum ALT activity
 - (B) Decreases serum bilirubin concentration
 - (C) Decreases urine selenium excretion
 - (D) Increases serum chloride concentration
 - (E) Increases urine copper excretion
 - (F) Increases urine lead excretion
18. A 60-year-old woman comes to the physician because she recently was diagnosed with non-small cell lung carcinoma and she wants to discuss possible treatment options. She tells the physician that she is concerned about the possible adverse effects of chemotherapy. The physician says that serious toxicity caused by antineoplastic drugs is seen in the bone marrow. Which of the following best explains this finding?
- (A) Cells in the marrow divide rapidly
 - (B) Cells in the marrow have specific surface targets for most of these drugs
 - (C) Cells in the marrow lack the enzymes to protect against the drugs
 - (D) Chemotherapy drugs act preferentially against cells with no nucleus
 - (E) Chemotherapy drugs penetrate well into the marrow because it is very vascular
 - (F) Chemotherapy drugs tend to be lipid-soluble and concentrate in the marrow
19. A 38-year-old woman with an 18-year history of type 1 diabetes mellitus and progressive renal failure is being considered for dialysis. Laboratory studies show normocytic, normochromic anemia. Which of the following medications is most appropriate to treat the anemia in this patient?
- (A) Erythropoietin
 - (B) Folic acid
 - (C) Folinic acid
 - (D) Vitamin B₁ (thiamine)
 - (E) Vitamin B₁₂ (cyanocobalamin)
20. A 47-year-old woman is admitted to the hospital for treatment of pneumococcal pneumonia. Treatment with gentamicin and penicillin is initiated. Within 10 minutes of the administration of antimicrobial therapy, her respirations increase to 30/min, and blood pressure decreases to 80/40 mm Hg. Epinephrine, antihistamine, and corticosteroid therapy is started. Her condition improves slowly during the next 2 hours. Her antimicrobial therapy is changed to gentamicin only, and her condition continues to improve. Administration of which of the following types of drugs is most likely to cause a similar adverse reaction in this patient?
- (A) Cephalosporins
 - (B) Macrolides
 - (C) Quinolones
 - (D) Tetracyclines

Answer Form for Pharmacology Sample Questions

(Questions 1-20)

1. _____
2. _____
3. _____
4. _____
5. _____
6. _____
7. _____
8. _____
9. _____
10. _____

11. _____
12. _____
13. _____
14. _____
15. _____
16. _____
17. _____
18. _____
19. _____
20. _____

Answer Key for Pharmacology Sample Questions

(Questions 1-20)

- | | | | |
|-----|---|-----|---|
| 1. | E | 11. | F |
| 2. | B | 12. | B |
| 3. | B | 13. | A |
| 4. | G | 14. | A |
| 5. | A | 15. | E |
| 6. | D | 16. | D |
| 7. | A | 17. | E |
| 8. | C | 18. | A |
| 9. | D | 19. | A |
| 10. | B | 20. | A |

PHYSIOLOGY

Cell Biology	10%–15%
Multisystem Processes (Nutrition, Acid-Base, Temperature/Environment)	10%–15%
Organ Systems	
Skin & related connective tissue	1%–5%
Musculoskeletal	1%–5%
Respiratory	5%–10%
Cardiovascular	15%–20%
Gastrointestinal	10%–15%
Renal/urinary	15%–20%
Reproductive	5%–10%
Endocrine	5%–10%

1. A hormone is known to activate phospholipase C with subsequent release of calcium from internal stores. The release of calcium most likely occurs as a result of an increase in the concentration of which of the following intracellular second messengers?
 - (A) Calcium
 - (B) cAMP
 - (C) cGMP
 - (D) Diacylglycerol
 - (E) Inositol 1,4,5-trisphosphate
2. A 28-year-old man with a history of intravenous drug use comes to the physician because of a 6-week history of fever, nonproductive cough, chills, and progressive shortness of breath. His temperature is 39°C (102.2°F), pulse is 110/min, respirations are 32/min and regular, and blood pressure is 120/80 mm Hg. Physical examination shows a white, patchy, loosely adherent exudate on the buccal mucosa bilaterally. A chest x-ray shows bilateral interstitial infiltrates. After receiving treatment for pneumonia, he agrees to participate in a clinical study of the effects of interleukin-2 (IL-2). After administration of IL-2, which of the following hematologic changes is most likely in this patient?
 - (A) Decreased CD4+ T lymphocytes
 - (B) Decreased erythrocytes
 - (C) Decreased platelet count
 - (D) Increased CD4+ T lymphocytes
 - (E) Increased erythrocytes
 - (F) Increased platelet count
3. A 5-year-old girl falls through the ice while skating on an outdoor pond. She is removed from the water within 1 minute, but dry clothing is not available, and she is still cold and wet 20 minutes later. Which of the following mechanisms helps maintain the patient's core temperature during the period following her rescue?
 - (A) Cutaneous vasodilation
 - (B) Diving response
 - (C) Increased thermoregulatory set point
 - (D) Release of endogenous pyrogen
 - (E) Shivering
4. A 39-year-old woman comes to the physician for a follow-up examination because she recently was diagnosed with hypertension. Her blood pressure is 156/100 mm Hg. Physical examination shows no other abnormalities. Serum studies show normal findings. A 24-hour urine collection shows three times the normal excretion of epinephrine and metanephrine. The excessive epinephrine production in this patient is most likely caused by which of the following cell types?
 - (A) Chromaffin
 - (B) Juxtaglomerular
 - (C) Zona fasciculata
 - (D) Zona glomerulosa
 - (E) Zona reticularis

5. The blood flow through an organ is measured while the perfusion pressure is varied experimentally. An abrupt, sustained increase in perfusion pressure increases flow initially, but over the course of 1 minute, the flow returns nearly to the baseline level despite continued elevation of the perfusion pressure. The organ under study is exhibiting which of the following?
- (A) Active hyperemia
 - (B) Autoregulation
 - (C) Ischemia
 - (D) Reactive hyperemia
6. After an overnight fast, a 52-year-old man undergoes infusion of acid through a catheter into the upper duodenum. This most likely will increase pancreatic secretion mainly through the action of which of the following substances?
- (A) Cholecystokinin
 - (B) Gastrin
 - (C) Glucagon
 - (D) Secretin
 - (E) Vasoactive intestinal polypeptide
7. A 20-year-old woman is brought to the emergency department 20 minutes after being stung by a wasp. She says that she feels a lump in her throat and chest tightness. She has a history of allergy to wasp venom. Her pulse is 120/min, and blood pressure is 80/40 mm Hg. Physical examination shows eruptions that coalesce into giant urticaria. There is audible wheezing. Which of the following best describes the cause of this patient's reaction?
- (A) Activation of macrophages by soluble immune complexes
 - (B) Binding of antigen to preexisting cell-fixed IgE antibodies
 - (C) Formation of IgG antibodies against extracellular matrix antigen
 - (D) Formation of IgM antibodies against cell surface receptor antigens
 - (E) Induction of a cytotoxic reaction by CD8+ T Lymphocytes
8. A demonstration is performed during a lecture on muscle physiology in which a student is asked to fully extend his right arm with the palm up. Two large textbooks are placed on his palm, one at a time. Which of the following facilitates the maximum amount of tension that allows the student to keep his arm extended in place under the increasing weight of the books?
- (A) Amount of Ca^{2+} released from the sarcoplasmic reticulum
 - (B) Amount of muscle phosphocreatine
 - (C) Amplitude of the action potential
 - (D) Number of motor units recruited
 - (E) Rate of cross-bridge recycling
9. During an experiment on the cough reflex in humans, a volunteer inhales air containing different amounts of particles that will impact and adhere to mucus primarily in the trachea. Blockade of which of the following receptors would most likely prevent this volunteer's reflex to initiate a cough?
- (A) Chemoreceptors
 - (B) Irritant receptors
 - (C) J receptors
 - (D) Proprioceptors
 - (E) Stretch receptors
10. A 35-year-old man has an adenoma of the parathyroid gland, with increased serum concentrations of parathyroid hormone (PTH) and calcium. In this patient, PTH induces which of the following processes to cause hypercalcemia?
- (A) Production of 25-hydroxycholecalciferol
 - (B) Shift of Ca^{2+} from the intracellular to the extracellular fluid compartment
 - (C) Stimulation of osteoclast activity
 - (D) Suppression of renal production of 1,25-dihydroxycholecalciferol
11. A female newborn delivered at 32 weeks' gestation develops severe respiratory distress within hours of birth. Despite resuscitative efforts, the patient dies. Examination of the lungs at autopsy shows lung alveoli with radii of less than 50 μm (N=100). Which of the following is most likely decreased in the lungs of this newborn?
- (A) Airway resistance
 - (B) Compliance
 - (C) Elastic recoil
 - (D) Surface tension
 - (E) Vascular resistance

12. A 55-year-old woman who is obese has a greater risk for endometrial carcinoma than a 55-year-old woman with the same health history and status who is not obese. Which of the following best explains this increased risk?

- (A) Accelerated catabolism of antioxidants
- (B) Association of obesity with smoking
- (C) Carcinogenic effects of dietary fats
- (D) Greater average number of pregnancies
- (E) Impairment of immune surveillance by T lymphocytes
- (F) Increased production of estrogen by adipose tissue
- (G) Later age of menopause
- (H) More frequent episodes of vaginitis

13. A 4-hour-old female newborn delivered at 30 weeks' gestation has respiratory distress. Her temperature is 36.5°C (97.7°F), pulse is 160/min, respirations are 85/min, and blood pressure is 68/40 mm Hg. Arterial blood gas analysis on room air shows:

pH	7.18
PCO ₂	78 mm Hg
PO ₂	55 mm Hg

Endotracheal intubation and mechanical ventilation are required. The primary cause of this patient's condition is a dysfunction of which of the following cell types?

- (A) Alveolar macrophages
- (B) Pneumocytes
- (C) Pulmonary chondrocytes
- (D) Pulmonary vascular endothelial cells
- (E) Smooth muscle cells

14. A 22-year-old man is brought to the emergency department because of a 6-hour history of severe, sharp, upper back pain. He has had progressive fatigue during the past 3 weeks. He is 183 cm (6 ft) tall and weighs 79 kg (175 lb); BMI is 24 kg/m². His temperature is 36.9°C (98.5°F), pulse is 90/min, and blood pressure is 160/55 mm Hg. Physical examination shows long, thin upper and lower extremities. Fingertip to fingertip with arms outstretched is 189 cm (74 in) wide. A high-pitched midsystolic click is heard predominantly over the apex. Which of the following best describes the primary genetic cause of this patient's condition?

- (A) Expression of genomic duplication within the fibrin gene
- (B) Mutation in keratin-14 gene
- (C) Nonsense mutation in fibrillin-1 gene
- (D) Overexpression of collagen X gene
- (E) Overexpression of fibronectin gene

15. A 25-year-old woman comes to the physician because of a 2-day history of muscle cramps and profuse, watery stools. She returned from a trip to Pakistan 3 days ago. Her temperature is 37°C (98.6°F), pulse is 120/min, and blood pressure is 80/50 mm Hg. Stool culture shows numerous curved, gram-negative bacteria; there are no erythrocytes or leukocytes. Oral rehydration is initiated. The blood pressure increases, and the pulse decreases. The oral hydration formula most likely promotes sodium absorption via the gut by allowing cotransport with which of the following?

- (A) Albumin
- (B) Fatty acid
- (C) Glucose
- (D) Magnesium
- (E) Potassium

16. A 26-year-old woman is brought to the emergency department because of a 4-day history of flu-like symptoms accompanied by vomiting following each attempt to eat or drink. Her temperature is 38.5°C (101.3°F), pulse is 93/min, respirations are 24/min, and blood pressure is 105/70 mm Hg. Physical examination shows no other abnormalities. Which of the following additional findings is most likely in this patient?

- (A) Decreased serum ADH (vasopressin) concentration
- (B) Increased serum aldosterone concentration
- (C) Increased serum atrial natriuretic peptide
- (D) Increased urine sodium and chloride concentrations
- (E) Increased urine volume

17. A 77-year-old man comes to the physician because of swelling of his legs and feet for 6 months. He has a 40-year history of alcoholism and a 5-year history of hepatic disease. Physical examination shows ascites and a 2+ edema of the lower extremities. A decrease in which of the following most likely promotes edema formation in this patient?

- (A) Capillary hydrostatic pressure
- (B) Filtration coefficient
- (C) Interstitial colloid osmotic pressure
- (D) Interstitial fluid hydrostatic pressure
- (E) Plasma colloid oncotic pressure

18. During a study of gastric parietal cells, an investigator attempts to elicit maximum hydrochloric acid secretion from the stomach of an experimental animal. Which of the following combinations of substances is most likely to lead to this desired effect?

	Acetylcholine	Gastrin	Histamine	Secretin
(A)	Increased	increased	increased	increased
(B)	Increased	increased	increased	decreased
(C)	Increased	decreased	decreased	increased
(D)	Decreased	increased	increased	increased
(E)	Decreased	decreased	increased	increased
(F)	Decreased	decreased	decreased	decreased
(G)	Decreased	decreased	decreased	decreased

19. A 30-year-old woman comes to the physician for a routine health maintenance examination. She takes no medications. Physical examination shows no abnormalities. Serum studies show a calcium concentration of 12 mg/dL. An increase in which of the following substances is the most likely cause of the serum finding in this patient?

- (A) Bone morphogenic protein
- (B) Calcitonin
- (C) Integrins
- (D) Parathyroid hormone
- (E) Vitamin A

20. A 28-year-old woman comes to the physician because of a 3-month history of shortness of breath with exertion. She takes an oral contraceptive. There are no occupational exposures to birds or grain dusts. Her respirations are 20/min. The lungs are clear to auscultation. Cardiac examination shows a regular rate and rhythm; S₂ is slightly louder than S₁. Cardiac catheterization shows a pulmonary artery pressure of 78/31 mm Hg (N=15–30/3–12) with a normal left ventricular end-diastolic pressure. Which of the following is most likely changed in this patient?

- (A) Decreased alveolar ventilation
- (B) Decreased left ventricular afterload
- (C) Increased muscle tone
- (D) Increased pulmonary compliance
- (E) Increased pulmonary vascular resistance

Answer Form for Physiology Sample Questions

(Questions 1-20)

1. _____
2. _____
3. _____
4. _____
5. _____
6. _____
7. _____
8. _____
9. _____
10. _____

11. _____
12. _____
13. _____
14. _____
15. _____
16. _____
17. _____
18. _____
19. _____
20. _____

Answer Key for Physiology Sample Questions

(Questions 1-20)

- | | | | |
|-----|---|-----|---|
| 1. | E | 11. | B |
| 2. | D | 12. | F |
| 3. | E | 13. | B |
| 4. | A | 14. | C |
| 5. | B | 15. | C |
| 6. | D | 16. | B |
| 7. | B | 17. | E |
| 8. | D | 18. | B |
| 9. | B | 19. | D |
| 10. | C | 20. | E |

CLINICAL NEUROLOGY

<i>General Principles</i>	1%–5%
<i>Organ Systems</i>	95%–99%
Mental Disorders	1%–5%
Diseases of the Nervous System and Special Senses	70%–90%
Disorders of the special senses	
Structural disorders (trauma, cerebrovascular disease, infections)	
Toxic, metabolic, and degenerative disorders	
Paroxysmal and sleep disorders	
Neuromuscular disorders	
Other Organ Systems	10%–15%
<i>Physician Task</i>	
Promoting Health and Health Maintenance	5%–10%
Understanding Mechanisms of Disease	15%–20%
Establishing a Diagnosis	50%–65%
Applying Principles of Management	15%–20%

1. A 39-year-old man is admitted to the hospital by his brother for evaluation of increasing forgetfulness and confusion during the past month. His brother reports that the patient has been drinking heavily and eating very little, and has been slightly nauseated and tremulous. He wanders at night because he cannot sleep. On admission to the hospital, intravenous administration of 5% dextrose in water is initiated. Two hours later, the patient has ophthalmoplegia and is completely confused. Which of the following is the most appropriate next step in management?
 - (A) Administration of an anticoagulant
 - (B) Administration of diazepam
 - (C) Administration of large doses of vitamin B₁ (thiamine), intravenously
 - (D) Administration of large doses of vitamin C, intravenously
 - (E) Continued administration of intravenous fluids with magnesium
2. A 47-year-old man comes to the physician because of a 2-year history of fatigue. He has had progressive difficulty with daytime sleepiness and has intermittently fallen asleep at work. He has no difficulty falling asleep or staying asleep at night but awakens in the morning not feeling well rested. His vital signs are within normal limits. Examination of the throat shows no abnormalities except for hypertrophied tonsils. His hemoglobin concentration is 17.9 g/dL, leukocyte count is 8700/mm³, and platelet count is 170,000/mm³. Which of the following is the most likely cause of this patient's symptoms?
 - (A) Chronic Epstein-Barr virus infection
 - (B) Chronic fatigue syndrome
 - (C) Erythroleukemia
 - (D) Polycythemia vera
 - (E) Sleep apnea
3. A 45-year-old man has had a 1-week history of increasing neck pain when he turns his head to the right. He also has had a pins-and-needles sensation starting in the neck and radiating down the right arm into the thumb. His symptoms began 3 months ago when he developed severe pain in the neck and right shoulder. Neurologic examination shows limitation of motion on turning the neck to the right. There is 4+/5 weakness of the right biceps and decreased pinprick over the right thumb. Deep tendon reflexes are 1+ in the right biceps and brachioradialis; all others are 2+. Which of the following is the most likely diagnosis?
 - (A) Carpal tunnel syndrome
 - (B) Cervical root compression
 - (C) Multiple sclerosis
 - (D) Thoracic outlet syndrome
 - (E) Ulnar nerve compression
4. A 29-year-old man is brought to the emergency department because he has a severe bilateral headache and irritability. His pulse is 120/min, respirations are 30/min, and blood pressure is 200/120 mm Hg. Ophthalmoscopic examination shows blurring of the optic discs. Deep tendon reflexes are 3+ and symmetric. Which of the following is the most likely diagnosis?
 - (A) Alcohol intoxication
 - (B) Heavy metal poisoning
 - (C) Hypertensive encephalopathy
 - (D) Hyperthyroidism
 - (E) Panic disorder

- (A) Alcohol-induced amnesic episode (blackout)
- (B) Alcohol withdrawal
- (C) Apathetic hyperthyroidism
- (D) Bipolar disorder, depressed
- (E) Delirium because of medical condition
- (F) Dementia, alcohol-related
- (G) Dementia, Alzheimer type
- (H) Generalized anxiety disorder
- (I) Masked depression
- (J) Medication toxicity
- (K) Normal age-associated memory decline
- (L) Normal-pressure hydrocephalus
- (M) Parkinson disease
- (N) Pick disease
- (O) Pseudodementia
- (P) Residual schizophrenia
- (Q) Vascular dementia

For each patient with a memory problem, select the most likely diagnosis.

5. A 29-year-old woman with an 11-year history of bipolar disorder comes to the physician because she is concerned about memory loss during the past 2 weeks. She has had difficulty remembering appointments that she has made, and on one occasion, she got lost going to the health club where she has been a member for years. She has taken lithium carbonate for 8 years, and she has been taking a friend's diuretic for perimenstrual weight gain during the past 3 months. Physical examination shows a resting tremor of both hands and mild ataxia. On mental status examination, she is oriented to person, place, and time, but she recalls only one of three objects after 5 minutes.
6. A 63-year-old man is brought to the physician by his daughter because she is concerned about his memory loss during the past year. Yesterday he could not remember his 18-month-old granddaughter's name. Although he denies that there is any problem, she says he has been forgetful and becomes easily confused. There is no history of alcohol abuse. His temperature is 37°C (98.6°F), pulse is 77/min, respirations are 12/min, and blood pressure is 118/84 mm Hg. On mental status examination, his mood is normal. He is oriented to person and place but initially gives the wrong month, which he is able to correct. He recalls memories from his youth in great detail but only recalls one of three words after 5 minutes. He has difficulty recalling the names of common objects and does not remember the name of the current US president. Physical examination, laboratory studies, and thyroid function tests show no abnormalities.
-
7. A 65-year-old man has had increasingly severe headaches and diffuse muscle aches during the past 3 months. He also has a 1-month history of jaw pain when chewing food and decreasing visual acuity in his left eye. His temperature is 38°C (100.4°F). Visual acuity in his left eye is 20/100, and the left optic disc is slightly atrophic. His muscle strength is normal. Which of the following tests should be obtained next?
- (A) Measurement of erythrocyte sedimentation rate
 - (B) Antinuclear antibody assay
 - (C) Examination of cerebrospinal fluid
 - (D) CT scan of the head
 - (E) Electroencephalography
8. A 19-year-old woman comes to the physician because of a 3-month history of intermittent drooping of her left eyelid each evening and occasional difficulty chewing and swallowing. She also has had two episodes of double vision that occurred in the evening and resolved by the following morning. Examination shows no abnormalities except for slight ptosis on the right. Which of the following is the most likely diagnosis?
- (A) Acute intermittent porphyria
 - (B) Brain stem glioma
 - (C) Complex partial seizures
 - (D) Guillain-Barré syndrome
 - (E) Myasthenia gravis

9. A 72-year-old man is brought to the physician by his daughter because of a 2-day history of confusion, disorientation, and lethargy. He has had no weakness. He had a cerebral infarction 1 year ago and has been treated with daily aspirin since then. He is awake but lethargic. His temperature is 38.9°C (102°F), pulse is 82/min, respirations are 16/min, and blood pressure is 144/88 mm Hg. Physical examination shows no other abnormalities. He is disoriented to place and time but recognizes his daughter. Laboratory studies show:

Hemoglobin	11.1 g/dL
Leukocyte count	12,200/mm ³
Segmented neutrophils	60%
Eosinophils	2%
Lymphocytes	30%
Monocytes	8%
Serum	
Na ⁺	130 mEq/L
Cl ⁻	92 mEq/L
K ⁺	4.1 mEq/L
HCO ₃ ⁻	21 mEq/L
Urea nitrogen	29 mg/dL
Creatinine	1 mg/dL
Urine	
pH	7
Specific gravity	1.020
WBC	10/hpf
RBC	6/hpf
Bacteria	positive
Nitrates	positive

Which of the following is the most likely diagnosis?

- (A) Delirium
- (B) Dementia, Alzheimer type
- (C) Major depressive disorder
- (D) Parkinson disease
- (E) Vascular dementia

10. A 21-year-old college student comes to student health services requesting medication to help her sleep. Four days ago, she returned from a 1-year trip to India where she studied comparative religions. Since her return, she has been unable to fall asleep until 4 or 5 AM and has difficulty awakening before noon. She constantly feels tired, has difficulty concentrating, and does not feel ready to begin classes. Her appetite has not decreased, but she has an aversion to eating meat since following a vegetarian diet in India. She has no history of medical or psychiatric illness. She takes no medications and does not drink alcohol. She appears sleepy. She is 173 cm (5 ft 8 in) tall and weighs 54 kg (120 lb); BMI is 18 kg/m². Her pulse is 60/min, and blood pressure is 115/70 mm Hg. She is alert and oriented to person, place, and time. When asked to subtract serial sevens from 100, she begins accurately but then repeatedly loses track of the sequence. Which of the following is the most likely diagnosis?

- (A) Adjustment disorder with depressed mood
- (B) Bipolar disorder
- (C) Circadian rhythm sleep disorder
- (D) Major depressive disorder
- (E) Malingering
- (F) Primary insomnia

11. A 67-year-old woman comes to the physician for a follow-up examination. She had a pulmonary embolism and required treatment in the hospital for 3 weeks. She had a retroperitoneal hemorrhage; anticoagulant therapy was temporarily discontinued, and she underwent placement of an inferior vena cava (IVC) filter. She had a hematoma that was resolving on discharge from the hospital 2 weeks ago. Today, she says she has had a persistent sensation of tingling and numbness of her left thigh that she did not report in the hospital because she thought it would go away; the sensation has improved somewhat during the past week. Her only medication is warfarin. Vital signs are within normal limits. Examination of the skin shows no abnormalities. Muscle strength is normal. Sensation to light touch is decreased over a 5 × 5-cm area on the lateral aspect of the left anterior thigh. Which of the following is the most likely cause of this patient's decreased sensation?

- (A) Cerebral infarction during the hospitalization
- (B) Complication of the IVC filter placement
- (C) Compression of the lateral femoral cutaneous nerve
- (D) Hematoma of the left thigh
- (E) Spinal cord infarct
- (F) Vitamin B₁₂ (cobalamin) deficiency

12. A 77-year-old woman is admitted to the hospital because of difficulty walking. She has had progressive pain and paresthesia of both feet over the past 3 weeks. She has a history of mild hypertension treated with hydrochlorothiazide and hypothyroidism treated with thyroid replacement therapy. Her pulse is 80/min, respirations are 16/min, and blood pressure is 150/80 mm Hg. Neurologic examination shows decreased ankle jerk reflexes bilaterally and decreased vibratory sense and proprioception in the lower extremities. Laboratory studies show:

Hemoglobin	10 g/dL
Leukocyte count	11,000/mm ³ with a normal differential
Mean corpuscular volume	106 μm ³
Serum	
K ⁺	4.1 mEq/L
Urea nitrogen	8 mg/dL
Creatinine	1.1 mg/dL
Glucose	110 mg/dL

Which of the following is the most likely diagnosis?

- (A) Diabetic neuropathy
- (B) Hypothyroidism
- (C) Pulmonary osteoarthropathy
- (D) Spinal stenosis
- (E) Vitamin B₁₂ (cobalamin) deficiency

-
13. An 82-year-old man is admitted to the hospital because nursing staff in his skilled nursing care facility report that he has appeared sad and depressed during the past 2 months. It is reported that he has a history of psychiatric illness, but details are not provided. He has been taking olanzapine, paroxetine, and haloperidol for 2 years. He does not appear to be in acute distress. He is 160 cm (5 ft 3 in) tall and weighs 48 kg (105 lb); BMI is 19 kg/m². Physical examination shows 2+ cogwheel rigidity of the upper extremities. Neurologic examination shows psychomotor retardation. On mental status examination, he is alert and generally pleasant and cooperative. His affect has little intensity or range. He says he does not feel depressed or anxious. Laboratory findings are within the reference range. Which of the following is the most likely cause of this patient's current symptoms?

- (A) Adjustment disorder
- (B) Akathisia
- (C) Dementia, Alzheimer type
- (D) Drug-induced parkinsonism
- (E) Major depressive disorder

15. A 27-year-old woman comes to the physician because of a 3-week history of fatigue and blurred vision. She occasionally has had double vision during this period. For the past year, she has had 3- to 4-day episodes of numbness and tingling of her arms and legs. She has no personal or family history of serious illness. Her only medication is an oral contraceptive. She has smoked one pack of cigarettes daily for 5 years. Vital signs are within normal limits. Funduscopic examination shows no abnormalities. Visual acuity is decreased in the left eye. Sensation to light touch is decreased over the hands and feet; sensation to pinprick is increased over the fingers and toes bilaterally. An MRI of the brain shows several hyperintense oval plaques in the periventricular region on T2-weighted images. Which of the following is the most likely diagnosis?

- (A) Glioma
- (B) Guillain-Barré syndrome
- (C) Multiple sclerosis
- (D) Systemic lupus erythematosus
- (E) Toxoplasmosis

14. A 25-year-old butcher has had severe episodic pain in his right thumb and right second and third digits for 2 months. The pain frequently awakens him from sleep. He has decreased sensation over the palmar surface of the thumb and index and long fingers of the right hand and atrophy of the thenar muscle mass. Compression of which of the following nerves is the most likely cause?

- (A) Median
- (B) Musculocutaneous
- (C) Posterior interosseous
- (D) Radial
- (E) Ulnar

16. A 57-year-old woman comes to the physician because of a 2-year history of difficulty sleeping. After she gets into bed at night, her legs feel cold and crampy, and she cannot settle into a comfortable position. Walking around temporarily relieves her symptoms. She also has difficulty sitting for a prolonged period of time. She has a mild anxiety disorder but takes no medications. Vital signs are within normal limits. Examination shows no abnormalities. Which of the following is the most likely diagnosis?
- Benign fasciculations
 - Major depressive disorder
 - Parkinson disease
 - REM sleep behavior disorder
 - Restless legs syndrome
 - Stiff-person syndrome
17. A 77-year-old man comes to the emergency department 1 hour after a 15-minute episode of right arm weakness and an inability to speak in sentences; the symptoms have now resolved. He has a 30-year history of hypertension treated with hydrochlorothiazide. He does not have diabetes mellitus or coronary artery disease. During the past 8 weeks, he has walked 3 miles daily without symptoms. His pulse is 80/min, respirations are 14/min, and blood pressure is 144/88 mm Hg. Examination, including cardiopulmonary and neurologic examinations, shows no other abnormalities. A carotid bruit is heard on the left. An ECG shows a normal sinus rhythm with a ventricular rate of 76/min. Echocardiography shows no abnormalities. Carotid duplex ultrasonography and follow-up MR angiography show an 80% left internal carotid stenosis. Which of the following is the most appropriate next step to prevent cerebral infarction in this patient?
- Prophylactic atorvastatin
 - Prophylactic naproxen
 - Prophylactic warfarin
 - Carotid endarterectomy
 - Extracranial-intracranial bypass surgery
 - Percutaneous coronary intervention
18. A 62-year-old man with alcoholism is admitted to the hospital because of somnolence and hepatic failure. On admission, his serum sodium concentration is 109 mEq/L. Hypertonic saline is administered, and the next day his serum sodium concentration is 138 mEq/L. Three days after admission, he has severe weakness; neurologic examination shows flaccid paresis of both the upper and lower extremities. Which of the following is the most likely cause of this patient's acute neurologic symptoms?
- Alcohol withdrawal
 - Central pontine myelinolysis
 - Hepatic encephalopathy
 - Hepatorenal syndrome
 - Vitamin B₁ (thiamine) deficiency
19. A 32-year-old woman comes to the emergency department 3 hours after the sudden onset of a severe headache. The pain is associated with nausea and vomiting. Medical history is noncontributory. She is drowsy but easy to arouse. Her temperature is 37.1°C (98.8°F), pulse is 92/min, respirations are 10/min, and blood pressure is 130/70 mm Hg. Examination of the head shows no abnormalities. Flexion of the neck produces pain. The optic fundi are normal. Motor and sensory examinations show no abnormalities. Cranial nerves are intact. Deep tendon reflexes are symmetric. Babinski sign is present bilaterally. Which of the following is most likely to confirm the diagnosis?
- X-rays of the sinuses
 - Carotid duplex ultrasonography
 - EEG
 - CT scan of the head
 - Biopsy of the temporal artery
20. A previously healthy 4-year-old boy is brought to the emergency department 8 hours after the onset of fever and a diffuse, constant headache. He had been well until 2 days ago when he developed malaise. Yesterday, he slept more than usual and had temperatures to 39.2°C (102.5°F). Immunizations are up-to-date. He is lethargic and irritable when aroused. He holds his head extended and cries when his neck is flexed. Muscle strength is normal, and deep tendon reflexes are symmetrically increased. A lumbar puncture yields turbid cerebrospinal fluid. Laboratory studies show:
- | | |
|-----------------------|-------------------------|
| Serum glucose | 120 mg/dL |
| Cerebrospinal fluid | |
| Opening pressure | 250 mm H ₂ O |
| Glucose | 10 mg/dL |
| Protein | 85 mg/dL |
| Leukocyte count | 750/mm ³ |
| Segmented neutrophils | 95% |
| Lymphocytes | 5% |
| Erythrocyte count | 0/mm ³ |
- A Gram stain of cerebrospinal fluid shows gram-negative diplococci. A CT scan of the head shows no abnormalities. Which of the following is the most likely causal organism?
- Cytomegalovirus
 - Haemophilus influenzae*
 - Neisseria meningitidis*
 - Streptococcus agalactiae* (group B)
 - Varicella-zoster virus

Answer Form for Clinical Neurology Sample Questions

(Questions 1-20)

- | | |
|-----------|-----------|
| 1. _____ | 11. _____ |
| 2. _____ | 12. _____ |
| 3. _____ | 13. _____ |
| 4. _____ | 14. _____ |
| 5. _____ | 15. _____ |
| 6. _____ | 16. _____ |
| 7. _____ | 17. _____ |
| 8. _____ | 18. _____ |
| 9. _____ | 19. _____ |
| 10. _____ | 20. _____ |

Answer Key for Clinical Neurology Sample Questions

(Questions 1-20)

- | | | | |
|-----|---|-----|---|
| 1. | C | 11. | C |
| 2. | E | 12. | E |
| 3. | B | 13. | D |
| 4. | C | 14. | A |
| 5. | J | 15. | C |
| 6. | G | 16. | E |
| 7. | A | 17. | D |
| 8. | E | 18. | B |
| 9. | A | 19. | D |
| 10. | C | 20. | C |

FAMILY MEDICINE

The Family Medicine examination predominantly comprises patient encounters in an ambulatory setting.

<i>General Principles</i>	1%–5%
<i>Organ Systems</i>	95%–99%
Immunologic Disorders	5%–10%
Diseases of the Blood and Blood-forming Organs	5%–10%
Mental Disorders	5%–10%
Diseases of the Nervous System and Special Senses	5%–10%
Cardiovascular Disorders	10%–15%
Diseases of the Respiratory System	10%–15%
Nutritional and Digestive Disorders	10%–15%
Gynecologic Disorders	5%–10%
Renal, Urinary, and Male Reproductive System	5%–10%
Disorders of Pregnancy, Childbirth, and the Puerperium	1%–5%
Disorders of the Skin and Subcutaneous Tissues	1%–5%
Diseases of the Musculoskeletal System and Connective Tissue	5%–10%
Endocrine and Metabolic Disorders	5%–10%
<i>Physician Task</i>	
Promoting Health and Health Maintenance	15%–20%
Understanding Mechanisms of Disease	20%–25%
Establishing a Diagnosis	35%–40%
Applying Principles of Management	20%–25%
<i>Distribution Across Age Groups</i>	
Childhood	5%–15%
Adolescence	5%–10%
Adulthood	65%–75%
Geriatric	5%–15%

-
1. An 18-year-old college student is brought to the emergency department by her friend because she has been crying for 3 hours. The friend reports that earlier in the day the patient gave away her books, furniture, and other personal items as gifts to friends and spent the rest of the day writing letters and crying. The patient states that she is displeased with her academic performance and upset about a recent failed relationship. She has not been sleeping well. Which of the following is the most appropriate next step in management?
 - (A) Recommend a study skills course
 - (B) Arrange a family conference
 - (C) Prescribe a benzodiazepine
 - (D) Prescribe a tricyclic antidepressant
 - (E) Immediate psychiatric evaluation
 2. A 23-year-old man comes to the physician because of a 1-week history of painful urination and a clear urethral discharge. One month ago, he had similar symptoms and completed a course of doxycycline therapy for a chlamydial infection. He has no previous history of sexually transmitted diseases. He has been sexually active with one female partner for 2 years, and she takes an oral contraceptive. Examination shows no abnormalities. A urine polymerase chain reaction test is positive for *Chlamydia trachomatis*. In addition to resuming doxycycline therapy, which of the following is the most appropriate next step?
 - (A) Recommend testing for his partner
 - (B) Obtain a urethral culture
 - (C) Order a pelvic ultrasonography
 - (D) Order a voiding cystourethrography
 - (E) Begin acyclovir therapy

3. A 37-year-old woman comes to the physician because of a 3-year history of intermittent, mild, diffuse abdominal cramps and bloating. Her symptoms occur after meals and are relieved with bowel movements. She also has constipation four to six times monthly. She says the constipation resolves spontaneously, but she sometimes has diarrhea for 1 to 2 days afterwards. She has not had any other symptoms. She has no history of serious illness and takes no medications. Examination shows no abnormalities. Which of the following is the most likely diagnosis?
- (A) Collagenous colitis
 - (B) Colon cancer
 - (C) Diverticulosis
 - (D) Inflammatory bowel disease
 - (E) Irritable bowel syndrome
4. A 17-year-old boy comes to the physician for a precollege examination. He has no history of serious illness. He does not smoke cigarettes or drink alcohol. He is not currently sexually active. Examination shows no abnormalities. During a discussion of sexual activity, the patient acknowledges that abstinence is the most effective method of avoiding infection with transmitted diseases but says he is thinking about becoming sexually active. He asks for advice about safe sex. Which of the following is the most appropriate recommendation for this patient?
- (A) Avoiding oral sex
 - (B) Avoiding symptomatic partners
 - (C) Consistent condom use
 - (D) Limiting his number of sexual partners
 - (E) Antibiotic prophylaxis
5. A 14-year-old boy with a 9-year history of type 1 diabetes mellitus has become increasingly noncompliant with his medication regimen. He occasionally refuses the mixture of short-acting and intermediate-acting insulin, which is administered subcutaneously by his mother twice daily. His mother reports that his behavior and eating patterns are increasingly erratic. Which of the following is the most appropriate next step?
- (A) Reassure the mother that such difficulties are common at this age
 - (B) Encourage the father to take a more prominent role in the patient's care
 - (C) Advise the mother of the risk for long-term complications without better compliance
 - (D) Assess the patient's understanding of his illness and willingness to manage his own disease
 - (E) Change the injection schedule to once daily
6. A 38-year-old woman has had eight to ten episodes of shortness of breath during the past 2 years. The episodes begin with a sensation of tightness in the chest that gradually increases over 24 hours and lasts up to 2 days. Audible wheezing and a slight cough occur during severe episodes. She feels well between episodes. Physical examination shows no abnormalities except mild prolongation of expiration. Which of the following is the most likely diagnosis?
- (A) Chronic aspiration
 - (B) Congestive heart failure
 - (C) Hyperventilation syndrome
 - (D) Intrinsic asthma
 - (E) Periarthritis nodosa
7. A 50-year-old man has had progressive weakness and shortness of breath with exertion for 3 months. He appears malnourished; conjunctivae are pale, and there are scattered petechiae. Laboratory studies show:
- | | |
|-------------------------|--|
| Hemoglobin | 6 g/dL |
| Mean corpuscular volume | 115 μm^3 |
| Leukocyte count | 2500/mm ³ with hypersegmented neutrophils |
| Reticulocyte count | 0.5% |
| Platelet count | 60,000/mm ³ |
- The most likely cause of his condition is a deficiency of which of the following?
- (A) Folic acid
 - (B) Iron
 - (C) Vitamin B₁ (thiamine)
 - (D) Vitamin B₆
 - (E) Vitamin C
8. A 19-year-old football player is brought to the emergency department after collapsing during practice. His father died suddenly at the age of 25 years during military basic training. The patient's pulse is 120/min, regular, and weak; respirations are 25/min and shallow; and blood pressure is 90/40 mm Hg. A loud holosystolic murmur is heard at the apex and right upper sternal border with no clicks or thrills. Which of the following is the most likely diagnosis?
- (A) Aortic stenosis
 - (B) Hypertrophic obstructive cardiomyopathy
 - (C) Primary pulmonary hypertension
 - (D) Pulmonary valve stenosis
 - (E) Rheumatic mitral stenosis

9. A 27-year-old nulligravid woman comes to the physician because of irregular menses for 10 months. During this time, she has been unable to conceive and has had frequent constipation, cold intolerance, and fatigue. She has not had headache or visual changes. Menses previously occurred at regular 30-day intervals and lasted 5 days. She is 163 cm (5 ft 4 in) tall and weighs 58 kg (128 lb); BMI is 22 kg/m². Her temperature is 37°C (98.6°F), pulse is 84/min, respirations are 18/min, and blood pressure is 120/70 mm Hg. Physical examination, including pelvic examination, shows no abnormalities. Serum studies show:

Thyroid stimulating hormone	40 µU/mL
Estradiol	40 pg/mL (N=30–400)
β-hCG	<2 mIU/mL
Prolactin	10 ng/mL

Which of the following is the most appropriate pharmacotherapy?

- (A) Cabergoline
- (B) Clomiphene
- (C) Ethinyl estradiol
- (D) Ibuprofen
- (E) Levothyroxine

-
10. A 25-year-old woman comes to the physician because of a 1-month history of constant fatigue and decreased motivation. She is a graduate student and is concerned because her academic performance is declining. She is not sad but has had progressive feelings of worthlessness and describes herself as feeling numb. She no longer takes pleasure in activities that she used to enjoy. She has difficulty concentrating and falling asleep and frequently awakens during the night. She also has had a 2.3-kg (5-lb) weight loss that she attributes to a decreased appetite. She has to force herself to eat. She has no history of serious illness and takes no medications. She has increased her alcohol intake during the past week to three glasses of red wine daily. Physical examination shows no abnormalities. Mental status examination shows moderate psychomotor retardation and a blunted affect. When asked about suicidal ideation, she says she thinks about death and sometimes wonders what the point of living is but does not have suicidal thoughts. Which of the following is the most appropriate pharmacotherapy?
- (A) Chlorpromazine
 - (B) Haloperidol
 - (C) Lorazepam
 - (D) Paroxetine
 - (E) Phenelzine
 - (F) Topiramate
11. A 6-month-old girl has had a flat, bluish discoloration over her sacrum since birth. The rash measures 7 × 9 cm and has irregular but defined borders. Which of the following is the most likely diagnosis?
- (A) Actinic keratosis
 - (B) Hairy nevus
 - (C) Juvenile melanoma
 - (D) Malignant melanoma
 - (E) Mongolian spot
 - (F) Nevus flammeus
 - (G) Strawberry hemangioma
12. A 25-year-old man comes to the physician because of a 2-day history of fever. He uses intravenous illicit drugs. His temperature is 39.4°C (103°F). A grade 3/6 systolic murmur is heard at the lower left sternal border. The right knee is swollen, warm, and tender; extension is limited by pain. His hematocrit is 35%, and erythrocyte sedimentation rate is 70 mm/h. A serum rheumatoid factor titer is positive at 1:640. Which of the following is the most likely cause of this patient's knee findings?
- (A) Gouty arthritis
 - (B) Rheumatoid arthritis
 - (C) Septic arthritis
 - (D) Synovitis
 - (E) Systemic lupus erythematosus
13. A 72-year-old woman comes to the physician in October for a routine health maintenance examination. She feels well and asks about which immunizations she should be receiving. During her previous routine examination last year, she received influenza and pneumococcal vaccines. Two years ago, she received a tetanus vaccine after she cut herself with the lid of a tin can. She has hypertension treated with a diuretic. She is active and lives independently with her husband. She is 157 cm (5 ft 2 in) tall and weighs 72 kg (160 lb); BMI is 29 kg/m². Her temperature is 37°C (98.6°F), pulse is 80/min, respirations are 20/min, and blood pressure is 130/70 mm Hg. Physical examination shows no other abnormalities. Which of the following vaccines is most appropriate to administer at this time?
- (A) Diphtheria-tetanus toxoid
 - (B) Influenza virus
 - (C) Measles-mumps-rubella
 - (D) Pneumococcal

14. A 16-year-old boy is brought to the physician by his parents because of fatigue, oversleeping, and deteriorating school performance over the past 4 months. His parents state that he occasionally appears exuberant and has bloodshot eyes; he recently exhibited strange behavior at a family reunion. He has a history of binge eating and a 6.8-kg (15-lb) weight gain over the past 6 months. Which of the following is the most likely explanation for this condition?
- (A) Alcohol abuse
 - (B) Amphetamine abuse
 - (C) Bulimia nervosa
 - (D) Cannabis abuse
 - (E) Inhalant intoxication
15. An 18-year-old college student comes to student health services 12 hours after her partner's condom broke during sexual intercourse. Her last menstrual period was approximately 3 weeks ago, but she states that since starting her freshman year, menses have occurred at irregular 28- to 40-day intervals. Examination shows no abnormalities. She is concerned about her risk for pregnancy. Which of the following is the most appropriate advice for this patient?
- (A) Reassurance that the patient is 1 week past the time of ovulation
 - (B) Advise the patient that too much time has passed to prevent pregnancy
 - (C) Spermicidal douche
 - (D) Oral contraceptives once daily for 1 month
 - (E) One levonorgestrel tablet now and again in 12 hours
 - (F) Dilatation and curettage within 24 hours
16. A 7-year-old boy is brought to the physician because of poor school performance during the past 6 months. He had been achieving all developmental milestones and had done well last year in first grade, but his teacher this year reports that he seems unable to understand the concepts of letters and numbers. He also has had behavioral problems and at times exhibits aggressive behavior toward other children. His parents feel he has had trouble adjusting to disruption in his life caused by a family move to an older home in the inner city. Examination shows no abnormalities. Which of the following is the most appropriate next step in diagnosis?
- (A) Karyotype analysis
 - (B) Measurement of blood lead concentration
 - (C) EEG
 - (D) MRI of the brain
 - (E) Cerebrospinal fluid analysis
17. A 42-year-old woman comes to the emergency department because of a 3-hour history of blood in her urine. During the past 2 days, she has had painful and frequent urination. She has no history of medical or gynecologic illness or abnormal Pap smears. She takes no medications and has no known drug allergies. She is sexually active with her husband, and they use foam and condoms for contraception. Vital signs are within normal limits. Examination shows moderate suprapubic tenderness. The remainder of the examination shows no abnormalities. Which of the following is the most likely causal organism?
- (A) *Escherichia coli*
 - (B) *Haemophilus ducreyi*
 - (C) *Neisseria gonorrhoeae*
 - (D) *Peptostreptococcus anaerobius*
 - (E) *Pseudomonas aeruginosa*
18. An asymptomatic 47-year-old woman comes to the physician for a follow-up examination. Six blood pressure readings during the past 3 months have ranged between 140/80 mm Hg and 150/90 mm Hg. She has a 5-year history of type 2 diabetes mellitus and hyperlipidemia. Current medications include an oral hypoglycemic agent and an HMG-CoA reductase inhibitor. Her mother has hypertension, coronary artery disease, and type 2 diabetes mellitus. The patient's blood pressure today is 160/90 mm Hg. Examination shows no other abnormalities. Serum studies show a glucose concentration of 178 mg/dL and creatinine concentration of 1.5 mg/dL. Urinalysis shows 1+ protein. Which of the following is the most appropriate medication to add to this patient's regimen?
- (A) ACE inhibitor
 - (B) β -Adrenergic blocking agent
 - (C) Calcium-channel blocking agent
 - (D) Loop diuretic
 - (E) No additional pharmacotherapy is indicated at this time
19. A previously healthy 13-month-old girl is brought to the physician in January by her mother because she has had watery, nonbloody diarrhea five times during the past 24 hours. She has had a low-grade fever and two episodes of vomiting during this period. She attends day care, and other children have had similar symptoms. She weighs 10 kg (22 lb), unchanged from 2 weeks ago. Her temperature is 37.7°C (100°F), pulse is 140/min, respirations are 24/min, and blood pressure is 90/58 mm Hg. Examination shows moist mucous membranes; the patient cries with tears. The extremities are warm with normal capillary refill time. The remainder of the examination shows no abnormalities. Which of the following is the most likely causal organism?
- (A) *Campylobacter jejuni*
 - (B) *Cryptosporidium parvum*
 - (C) *Giardia lamblia*
 - (D) Rotavirus
 - (E) *Salmonella enteritidis*

20. A 47-year-old man comes to the physician because of a 4-month history of generalized fatigue. During this period, he has had a decreased appetite resulting in a 7.3-kg (16-lb) weight loss. He has no history of serious illness. He occasionally takes an over-the-counter cough suppressant as needed. He has smoked two packs of cigarettes daily for 30 years. He drinks one to two beers daily. He is employed as an automobile mechanic. His paternal grandfather had bladder cancer, and a maternal aunt had endometrial cancer. He is 183 cm (6 ft) tall and weighs 68 kg (150 lb); BMI is 20 kg/m². His temperature is 37.2°C (99°F), pulse is 90/min, respirations are 20/min, and blood pressure is 122/64 mm Hg. Examination shows temporal wasting. Wheezing and rhonchi are heard throughout all lung fields. An x-ray of the chest shows multiple nodules bilaterally. A biopsy specimen of a nodule shows small cell carcinoma. Which of the following is the strongest predisposing factor for this patient's condition?
- (A) Age
 - (B) Exposure to asbestos
 - (C) Family history of multiple cancers
 - (D) Gender
 - (E) History of alcohol use
 - (F) History of smoking

Answer Form for Family Medicine Sample Questions

(Questions 1-20)

- | | |
|-----------|-----------|
| 1. _____ | 11. _____ |
| 2. _____ | 12. _____ |
| 3. _____ | 13. _____ |
| 4. _____ | 14. _____ |
| 5. _____ | 15. _____ |
| 6. _____ | 16. _____ |
| 7. _____ | 17. _____ |
| 8. _____ | 18. _____ |
| 9. _____ | 19. _____ |
| 10. _____ | 20. _____ |

Answer Key for Family Medicine Sample Questions

(Questions 1-20)

- | | | | |
|-----|---|-----|---|
| 1. | E | 11. | E |
| 2. | A | 12. | C |
| 3. | E | 13. | B |
| 4. | C | 14. | D |
| 5. | D | 15. | E |
| 6. | D | 16. | B |
| 7. | A | 17. | A |
| 8. | B | 18. | A |
| 9. | E | 19. | D |
| 10. | D | 20. | F |

MEDICINE

<i>General Principles</i>	1%–5%
<i>Organ Systems</i>	95%–99%
Immunologic Disorders	5%–10%
Diseases of the Blood and Blood-forming Organs	5%–10%
Diseases of the Nervous System and Special Senses	5%–10%
Cardiovascular Disorders	15%–20%
Diseases of the Respiratory System	15%–20%
Nutritional and Digestive Disorders	10%–15%
Gynecologic Disorders	1%–5%
Renal, Urinary, and Male Reproductive System	10%–15%
Disorders of the Skin and Subcutaneous Tissues	5%–10%
Diseases of the Musculoskeletal System and Connective Tissue	5%–10%
Endocrine and Metabolic Disorders	5%–10%
<i>Physician Tasks</i>	
Promoting Health and Health Maintenance	10%–15%
Understanding Mechanisms of Disease	20%–25%
Establishing a Diagnosis	40%–45%
Applying Principles of Management	20%–25%

1. A 22-year-old woman with a 10-year history of asthma comes to the physician because she has had to increase her use of her albuterol inhaler during the past 6 weeks. Her asthma was previously well controlled with inhaled glucocorticoids. She has a 2-year history of generalized anxiety disorder controlled with fluoxetine and a 5-year history of migraines. The migraines were well controlled with sumatriptan until 4 months ago when she began to have headaches twice weekly; propranolol was added to her regimen at that time. She has been taking an oral contraceptive for the past year. She says she has been under increased stress at graduate school and in her personal life during the past 3 months; during this period, she has been drinking an average of four cups of coffee daily (compared with her usual one cup daily). She does not drink alcohol or use illicit drugs. She appears mildly anxious but is not in respiratory distress. Scattered end-expiratory wheezes are heard. The remainder of the examination shows no abnormalities. Which of the following is the most likely cause of the exacerbation of this patient's asthma?
- (A) Fluoxetine therapy
(B) Increased caffeine intake
(C) Oral contraceptive therapy
(D) Propranolol therapy
(E) Sumatriptan therapy
2. A 28-year-old woman has palpitations that occur approximately once a week, last 1–5 minutes, and consist of rapid, regular heart pounding. The episodes start and stop suddenly and have not been associated with chest discomfort or dyspnea. There is no history of heart problems. She drinks two to three cups of coffee daily. She rarely drinks alcohol and does not smoke. Her pulse is 96/min and regular, and blood pressure is 120/88 mm Hg. A stare and lid lag are noted. The thyroid gland is firm and 1.5 times larger than normal. There is a midsystolic click at the apex and a grade 2/6, early systolic murmur at the upper left sternal border. An ECG is normal except for evidence of sinus tachycardia. Which of the following is the most appropriate next step in diagnosis?
- (A) Ambulatory ECG monitoring
(B) Measurement of serum thyroid-stimulating hormone concentration
(C) Measurement of urine catecholamine concentration
(D) MUGA scan
(E) Echocardiography

3. A study is conducted to assess the benefits of a new drug to reduce the recurrence of colonic polyps. The results show a number needed to treat (NNT) of 16. Which of the following is the most accurate interpretation of this result?

- (A) For every 16 patients treated, 1 would benefit from the new drug
- (B) For every 100 patients treated, 16 would benefit from the new drug
- (C) The new drug is 1.6 times more beneficial than a placebo
- (D) 93% of patients taking the new drug would benefit from it
- (E) 84% of patients taking the new drug would not have any benefit from it

4. A previously healthy 57-year-old woman comes to the physician 1 week after noticing a lump under her right arm. She is concerned that it is breast cancer because both her mother and maternal aunt died of breast cancer. She does not smoke, drink alcohol, or use illicit drugs. She has avoided the sun for the past 10 years. She notes that her skin has never tanned but always burned and freckled when exposed to the sun. She exercises daily on a stationary bicycle and eats a well-balanced diet. Her temperature is 37°C (98.6°F), pulse is 82/min and regular, respirations are 14/min, and blood pressure is 130/74 mm Hg. There are numerous freckles over the entire body. Examination of the right breast shows a 0.6-cm, flat, brown lesion; the lesion is mottled with deep purple and black areas and has an irregular border. There are no breast masses, dimpling, peau d'orange, or nipple discharge. The patient says that the lesion has been present for 1 year, but she has never had it examined. There is a firm, nontender mass in the right axilla. Examination shows no other abnormalities. Which of the following is the most likely diagnosis?

- (A) Basal cell carcinoma
- (B) Fibrocystic changes of the breast
- (C) Mastitis
- (D) Melanoma
- (E) Pigmented nevus
- (F) Port-wine stain
- (G) Squamous cell carcinoma
- (H) Superficial breast carcinoma

5. Two days after receiving 3 units of packed red blood cells for postpartum hemorrhage, a 24-year-old woman has fatigue and slight jaundice. Laboratory studies show:

Hemoglobin	8.8 g/dL
Hematocrit	28%
Serum total bilirubin	5 mg/dL

Liver tests are otherwise within normal limits. Which of the following is the most appropriate next step in diagnosis?

- (A) Cytomegalovirus antibody titer
- (B) Direct and indirect antiglobulin (Coombs) tests
- (C) Monospot test
- (D) Serology for hepatitis B markers
- (E) Ultrasonography of the gallbladder

6. A 30-year-old man has had nausea, vomiting, and severe colicky right flank pain radiating into the thigh for 4 hours. He is afebrile. There is right costovertebral angle tenderness. Urinalysis shows RBCs too numerous to count and no bacteria. Which of the following is the most likely diagnosis?

- (A) Acute glomerulonephritis
- (B) Bacterial cystitis
- (C) Benign prostatic hyperplasia
- (D) Bladder carcinoma
- (E) Renal cell carcinoma
- (F) Urinary tract tuberculosis
- (G) Urolithiasis

7. A 66-year-old woman comes to the emergency department 1 hour after the sudden onset of retrosternal chest discomfort accompanied by nausea and diaphoresis. She has hypotension, jugular venous distention, and a murmur of tricuspid regurgitation. An ECG shows ST-segment elevation in the right precordial leads. Which of the following is the most likely diagnosis?

- (A) Constrictive pericarditis
- (B) Dissecting aortic aneurysm
- (C) Pericardial tamponade
- (D) Pulmonary emboli
- (E) Right ventricular infarction

8. A 20-year-old African American woman comes to the physician because of a 6-month history of diffuse joint pain, especially in her hips and knees. During this period, she occasionally has had a rash on her nose and cheeks. She has no history of serious illness and takes no medications. Her temperature is 38.1°C (100.5°F). Examination shows warmth and swelling of the knees. Laboratory studies show:

Hemoglobin	10.5 g/dL
Erythrocyte sedimentation rate	40 mm/h
Serum	
Urea nitrogen	30 mg/dL
Creatinine	1.8 mg/dL

Which of the following is the most likely diagnosis?

- (A) Ankylosing spondylitis
 - (B) Gouty arthritis
 - (C) Psoriatic arthritis
 - (D) Reactive arthritis
 - (E) Rheumatoid arthritis
 - (F) Septic arthritis
 - (G) Systemic lupus erythematosus
-
9. A 37-year-old man with type 1 diabetes mellitus comes to the physician for a routine examination. His only medication is insulin. His pulse is 72/min, respirations are 12/min, and blood pressure is 138/88 mm Hg. Funduscopic examination shows microaneurysms and hemorrhages. Sensation to vibration and light touch is decreased over the lower extremities. His serum creatinine concentration is 1.6 mg/dL. A 24-hour urine collection shows 550 mg of protein. Treatment with which of the following is most likely to slow progression of this patient's renal disease?
- (A) Atenolol
 - (B) Clonidine
 - (C) Hydralazine
 - (D) Hydrochlorothiazide
 - (E) Lisinopril
10. A 50-year-old man is admitted to the hospital within 2 hours of the onset of nausea, vomiting, and acute crushing pain in the left anterior chest. He has a family history of early coronary artery disease. The pain does not subside with the administration of nitroglycerin, sublingually. An ECG shows ST-segment elevation in leads aVL and V₂ through V₄. Which of the following is the most appropriate management to decrease myocardial damage and mortality?
- (A) Administration of digitalis
 - (B) Administration of lidocaine
 - (C) Administration of quinidine
 - (D) Coronary artery bypass grafting within 1 week
 - (E) Thrombolytic therapy
11. A previously healthy 67-year-old woman comes to the physician with her husband because of a 4-month history of a resting tremor of her right arm. Her husband reports that her movements have been slower and that she appears less stable while walking. Examination shows increased muscle tone in the upper extremities that is greater on the right than on the left. There is decreased right arm swing. Her gait is slow and shuffling. Which of the following is the most likely explanation for this patient's symptoms?
- (A) Bilateral frontal lobe degeneration
 - (B) Decreased dopaminergic input to the striatum
 - (C) Decreased serotonergic activity in the brain stem
 - (D) Excessive output of oxytocin
 - (E) Excessive thalamic output of norepinephrine
12. A 47-year-old man comes to the physician because of a 4-week history of increased thirst and urination. He has had a 23-kg (50-lb) weight gain during the past 2 years. He has no history of serious illness and takes no medications. His mother and maternal grandfather have type 2 diabetes mellitus. The patient does not smoke and drinks one beer every night. He is 175 cm (5 ft 9 in) tall and now weighs 104 kg (230 lb); BMI is 34 kg/m². His pulse is 90/min, and blood pressure is 150/88 mm Hg. The remainder of the examination shows no abnormalities. His serum glucose concentration is 330 mg/dL. Which of the following is the most likely underlying cause of this patient's increased serum glucose concentration?
- (A) Autoimmune destruction of islet cells
 - (B) Chronic pancreatitis
 - (C) Exogenous production of corticosteroids
 - (D) Insulin resistance
 - (E) Pancreatic cancer

13. A previously healthy 39-year-old woman is brought to the physician because of a tingling sensation in her fingers and toes for 2 days and rapidly progressive weakness of her legs. She had an upper respiratory tract infection 2 weeks ago. She was unable to get up from bed this morning. Examination shows weakness of all four extremities, distal greater than proximal. Deep tendon reflexes are absent. Sensation is mildly decreased over the feet. Which of the following is the most likely diagnosis?
- (A) Guillain-Barré syndrome
 - (B) Multiple sclerosis
 - (C) Myasthenia gravis
 - (D) Poliomyelitis
 - (E) Tick paralysis
14. A previously healthy 77-year-old woman who resides in a skilled nursing care facility is brought to the emergency department 6 hours after the onset of acute midback pain that began while lifting a box. The pain does not radiate, and she has no other symptoms. She continues to carry out her daily activities. She appears to be in mild distress. She is 157 cm (5 ft 2 in) tall and weighs 47 kg (104 lb); BMI is 19 kg/m². Examination shows mild tenderness over T11. There is no tremor. Serum studies show a calcium concentration of 9.1 mg/dL, a urea nitrogen concentration of 12 mg/dL, and a creatinine concentration of 0.5 mg/dL. An x-ray of the dorsal and lumbar spine shows an anterior wedge fracture of T11. In addition to treating the pain, supplementation with which of the following is most likely to improve this patient's underlying condition?
- (A) 25-Hydroxycholecalciferol
 - (B) Levothyroxine
 - (C) Selenium
 - (D) Vitamin C
 - (E) Vitamin E
15. A 52-year-old woman comes to the physician because of a 3-month history of diarrhea and intermittent abdominal pain that radiates to her back. The pain is exacerbated by eating. She describes her stools as greasy, foul-smelling, and difficult to flush. She has had a 4.5-kg (10-lb) weight loss during the past 4 months. She has a history of chronic alcohol abuse. Examination shows mild epigastric tenderness. An x-ray of the abdomen shows calcifications in the epigastrium. Which of the following is the most likely diagnosis?
- (A) Bacterial overgrowth
 - (B) Celiac disease
 - (C) Lactose intolerance
 - (D) Malabsorption of bile salts
 - (E) Pancreatic insufficiency
16. A 67-year-old woman comes to the physician because of an 8-month history of progressive shortness of breath. The shortness of breath initially occurred only with walking long distances but now occurs after walking ¼ mile to her mailbox. She also has a daily morning cough productive of whitish tan sputum. She has had no chest pain, palpitations, orthopnea, or paroxysmal nocturnal dyspnea. She has smoked one pack of cigarettes daily for 52 years. Her pulse is 88/min, respirations are 20/min, and blood pressure is 144/90 mm Hg. Examination shows a barrel-shaped chest. Breath sounds are decreased, and faint expiratory wheezes are heard in all lung fields. There is no peripheral edema. An x-ray of the chest shows no abnormalities except for hyperinflation. Which of the following is the most likely diagnosis?
- (A) Angina pectoris
 - (B) Asthma
 - (C) Chronic obstructive pulmonary disease
 - (D) Chronic pulmonary embolism
 - (E) Congestive heart failure
 - (F) Panic disorder
17. A 22-year-old woman comes to the physician because of a 10-day history of pain in multiple joints. She first had pain in her right elbow, and then her right shoulder, and now has pain, redness, and swelling in her left knee that began 2 days ago. She currently has no pain in the right shoulder and elbow. There is no history of trauma. She is sexually active, and she and her partner use condoms for contraception inconsistently. Examination of the left knee shows warmth, erythema, tenderness, and soft-tissue swelling. Range of motion of the knee is limited to 10 degrees of flexion. The remainder of the examination, including pelvic examination, shows no abnormalities. Arthrocentesis of the knee joint yields 10 mL of cloudy fluid with a leukocyte count of 18,300/mm³ (97% segmented neutrophils). Microscopic examination of the leukocytes within the joint fluid is most likely to show which of the following?
- (A) Acid-fast bacteria
 - (B) Cuboidal positively birefringent crystals
 - (C) Gram-negative diplococci
 - (D) Gram-positive cocci in clusters
 - (E) Needle-shaped negatively birefringent crystals
18. A 47-year-old woman comes to the physician for a routine health maintenance examination. She feels well and has no history of serious illness. Her mother, brother, and sister have hypertension. The patient's pulse is 84/min, and blood pressure is 138/85 mm Hg. Examination shows no other abnormalities. The most appropriate recommendation is decreased intake of which of the following?
- (A) Calcium
 - (B) Carbohydrates
 - (C) Potassium
 - (D) Protein
 - (E) Sodium

19. A 32-year-old man comes to the physician because of a 12-day history of abdominal cramps and bloating, diarrhea, and flatulence. He says that he started a new exercise program 2 weeks ago and has been consuming a high quantity of yogurt bars, peanut butter, and protein- and calorie-enriched milk shakes to “bulk up.” He has no history of serious illness and takes no medications. His temperature is 37°C (98.6°F). The abdomen is distended, nontender, and tympanitic to percussion. Bowel sounds are increased. The remainder of the examination shows no abnormalities. Which of the following is the most likely cause of this patient’s symptoms?
- (A) Allergy to peanuts
 - (B) Fungal overgrowth in the small bowel
 - (C) Incarcerated hernia
 - (D) Irritable bowel syndrome
 - (E) Lactase deficiency
20. A 22-year-old college student comes to student health services because of a 7-day history of low-grade fever, sore throat, fatigue, and general malaise. One month ago, she had a painless vulvar ulcer that resolved spontaneously; she has been otherwise healthy. Her last menstrual period was 3 weeks ago; she uses tampons regularly. She is sexually active and has had three partners since the age of 15 years; she uses an oral contraceptive. Her temperature is 38°C (100.4°F), pulse is 100/min, and blood pressure is 110/60 mm Hg. Examination shows a rash over the palms and soles and mild cervical lymphadenopathy. Pelvic examination shows no abnormalities. Which of the following is the most appropriate pharmacotherapy?
- (A) Acyclovir
 - (B) Dexamethasone
 - (C) Interferon
 - (D) Penicillin
 - (E) Zidovudine (AZT)

Answer Form for Medicine Sample Questions

(Questions 1-20)

1. _____
2. _____
3. _____
4. _____
5. _____
6. _____
7. _____
8. _____
9. _____
10. _____

11. _____
12. _____
13. _____
14. _____
15. _____
16. _____
17. _____
18. _____
19. _____
20. _____

Answer Key for Medicine Sample Questions

(Questions 1-20)

- | | | | |
|-----|---|-----|---|
| 1. | D | 11. | B |
| 2. | B | 12. | D |
| 3. | A | 13. | A |
| 4. | D | 14. | A |
| 5. | B | 15. | E |
| 6. | G | 16. | C |
| 7. | E | 17. | C |
| 8. | G | 18. | E |
| 9. | E | 19. | E |
| 10. | E | 20. | D |

OBSTETRICS AND GYNECOLOGY

<i>General Principles</i>	1%–5%
<i>Gynecology</i>	45%–49%
Promoting Health and Health Maintenance	5%–10%
Understanding Mechanisms of Disease	15%–20%
Establishing a Diagnosis	15%–20%
Applying Principles of Management	5%–10%
<i>Obstetrics</i>	45%–49%
Promoting Health and Health Maintenance	5%–10%
Understanding Mechanisms of Disease	10%–15%
Establishing a Diagnosis	15%–20%
Applying Principles of Management	10%–15%

1. A 57-year-old woman comes to the physician 1 week after noticing a mass in her left breast during breast self-examination. Menopause occurred 6 months ago. She was receiving estrogen therapy but discontinued it 6 weeks ago; she has had no menopausal symptoms. There is no family history of breast cancer. Examination shows a 2-cm, palpable, nontender, mobile mass in the upper outer quadrant of the left breast; no nipple discharge can be expressed. Examination of the right breast shows no abnormalities. Which of the following is the most appropriate next step in management?

 - (A) Reexamination in 3 months
 - (B) Mammography
 - (C) CT scan of the chest
 - (D) Ductal lavage
 - (E) Mastectomy
2. A 27-year-old nulligravid woman has had severe pain with menses that has caused her to miss at least 2 days of work during each menstrual cycle for the past year. She has occasional pain during sexual intercourse. She weighs 50 kg (110 lb) and is 160 cm (5 ft 3 in) tall; BMI is 20 kg/m². Pelvic examination shows a normal-appearing vulva and vagina. The cervix is pink with minimal endocervical gland eversion. The uterus is normal in size. The left ovary is 2 × 3 cm; the right is 4 × 6 cm. Which of the following is the most likely cause of her condition?

 - (A) Chronic appendicitis
 - (B) Endometriosis
 - (C) Pelvic congestion syndrome
 - (D) Polycystic ovarian syndrome
 - (E) Premenstrual syndrome
3. A 22-year-old woman comes to the physician because of a 2-day history of pain with urination, intense vaginal itching, and a thick discharge. She has no history of serious illness. She is sexually active and uses an oral contraceptive. Her temperature is 37°C (98.6°F). Abdominal examination shows no abnormalities. Genitourinary examination shows erythema of the vulva and vagina with an odorless curd-like discharge. The cervix appears normal. Bimanual examination shows no abnormalities. The pH of the vaginal discharge is 4. Wet mount preparations of the discharge with saline and with KOH are obtained. The saline slide shows mature squamous epithelial cells, and the KOH slide shows multiple budding yeasts with pseudohyphae. Which of the following is the most likely diagnosis?

 - (A) Bacterial vaginosis
 - (B) Candidiasis
 - (C) *Chlamydia trachomatis* infection
 - (D) Lichen sclerosus
 - (E) Scabies
 - (F) Trichomoniasis
4. A 27-year-old nulligravid woman and her husband have been unable to conceive for 12 months. She has never used contraception. Menses occur at 28-day intervals, and her last menstrual period was 2 weeks ago. She had a single episode of pelvic inflammatory disease 4 years ago and was treated with oral antibiotics. Vaginal examination shows no abnormalities. Cervical cultures are normal. Which of the following is the most appropriate next step in diagnosis?

 - (A) Reevaluation in 6 months
 - (B) Ultrasonography of the abdomen
 - (C) Sperm penetration assay
 - (D) Hysterosalpingography
 - (E) Endometrial biopsy

5. A 30-year-old woman, gravida 2, para 1, comes for her first prenatal visit at 26 weeks' gestation. Uterine size is greater than expected for dates. Ultrasonography shows fetal hydrops. Which of the following is the most appropriate next step in diagnosis?
- Maternal HIV antibody test
 - Maternal Rh status with antibody screening
 - Cervical and urine cultures for group B streptococcus
 - MRI of the fetus
 - Amniocentesis for measurement of α -fetoprotein concentration
6. A 42-year-old woman, gravida 2, para 2, comes to the physician because of increasingly frequent loss of urine during the past year. She has loss of urine when she coughs, sneezes, exercises, or plays with her children. Her incontinence is never preceded by a sudden urge to void, and she does not have loss of urine at night. Her children were born after uncomplicated vaginal deliveries. She has no history of other hospital admissions or serious illness. She takes no medications. Abdominal examination shows no abnormalities. The external genitalia, vagina, and cervix appear normal. The uterus and adnexa are normal to palpation. There is loss of a small amount of urine with Valsalva maneuver. Her postvoid residual volume is 50 mL. Urinalysis shows no abnormalities. Which of the following is the most likely diagnosis?
- Overactive bladder with incontinence
 - Overflow incontinence
 - Stress incontinence
 - Urinary tract infection
 - Vesicovaginal fistula
7. During a routine examination, a 25-year-old woman expresses concern about her risk for ovarian cancer because her mother died of the disease. Which of the following is the most appropriate course of action?
- Reassure her that ovarian cancer is not hereditary
 - Obtain a more detailed family history of cancer
 - Recommend a diet high in beta-carotene
 - Annual CT scans of the abdomen
 - Prophylactic oophorectomy
8. At her 6-week postpartum visit, an 18-year-old woman, gravida 1, para 1, tells her physician that she has a pinkish vaginal discharge that has persisted since her delivery, although it is decreasing in amount. On physical examination, the uterus is fully involuted and there are no adnexal masses. Which of the following is the most appropriate next step in management?
- Reassurance that this is normal
 - Measurement of serum prolactin concentration
 - Quantitative β -hCG test
 - Administration of ampicillin
 - Dilatation and curettage
9. A 32-year-old nulligravid woman comes to the physician because of a 6-week history of persistent foul-smelling vaginal discharge and vaginal itching. Her symptoms have not improved despite 2 weeks of treatment with over-the-counter antifungal medications and fluconazole. She has been sexually active and monogamous with her boyfriend during the past year, and they use condoms consistently. Examination shows excoriated labia and erythematous vaginal mucosa. There is a frothy, watery-gray discharge in the posterior vaginal vault. A wet mount preparation of the discharge shows numerous multi-flagellated organisms the size of erythrocytes. Which of the following is the most likely causal organism?
- Haemophilus ducreyi*
 - Neisseria gonorrhoeae*
 - Pseudomonas aeruginosa*
 - Treponema pallidum*
 - Trichomonas vaginalis*
10. An asymptomatic 24-year-old primigravid woman at 36 weeks' gestation comes for a routine prenatal visit. A grade 2/6, systolic ejection murmur is heard at the upper left sternal border. The S₂ varies with inspiration, and the pulmonic component is soft; diastole is clear. Which of the following is the most likely diagnosis?
- Anomalous pulmonary venous return
 - Atrial septal defect
 - Flow murmur
 - Patent ductus arteriosus
 - Pulmonary valve stenosis
11. A 42-year-old woman, gravida 3, para 3, comes to the physician because she has not had a menstrual period for 2 months. She reports that she had an episode of spotting 3 weeks ago. She has had no other symptoms. She has no history of abnormal Pap smears; her last Pap smear was 10 months ago. She is sexually active with her husband and uses condoms. She is 163 cm (5 ft 4 in) tall and weighs 72 kg (160 lb); BMI is 28 kg/m². On physical examination, the abdomen is nontender to palpation. Pelvic examination shows a slightly enlarged uterus; there are no palpable adnexal masses. Which of the following is the most appropriate next step in management?
- Measurement of serum β -hCG concentration
 - Measurement of serum thyroid-stimulating hormone concentration
 - CT scan of the pelvis
 - Oral contraceptive therapy
 - Endometrial biopsy

12. A 57-year-old woman comes to the physician for a routine health maintenance examination. She takes a multivitamin supplement and calcium (500 mg/d). She has followed a vegan diet for 30 years. She exercises daily for 30 minutes. She does not smoke cigarettes or drink alcohol. There is a family history of osteoporosis. She is 168 cm (5 ft 6 in) tall and weighs 60 kg (132 lb); BMI is 21 kg/m². Examination shows no abnormalities. Bone densitometry shows evidence of low bone density. She prefers not to be treated with medications. The physician recommends that the patient increase her daily dose of the calcium supplement. The most appropriate next step in management is supplementation with which of the following?
- Fish oil
 - Magnesium
 - Vitamin C
 - Vitamin D
 - Zinc
13. A 2778-g (6-lb 2-oz) male newborn is born at 37 weeks' gestation to a 27-year-old woman, gravida 3, para 2, after an uncomplicated labor and delivery. The mother has no medical insurance and did not receive prenatal care. She says she did not have any health problems during pregnancy, but she continued to consume two bottles of beer weekly during her pregnancy. She does not take any medications, vitamins, or herbal supplements. Her diet consists mostly of rice and beans. Examination of the newborn shows spina bifida. Which of the following measures during the mother's pregnancy is most likely to have prevented this child's deformity?
- Abstinence from alcohol
 - Increase dietary intake of omega-3 fatty acids
 - Glucose tolerance test
 - Screening for group B streptococcal infection
 - TORCH titer screening
 - Folic acid supplementation
14. Two hours after vaginal delivery at term of a 3062-g (6-lb 12-oz) newborn, a 32-year-old woman, gravida 3, para 3, has the onset of heavy vaginal bleeding. Labor was augmented with oxytocin because of a prolonged first stage and required forceps delivery over a midline second-degree episiotomy. The abdomen is soft and nontender. Examination shows a boggy uterus palpated 4 cm above the umbilicus. The perineum is intact. Which of the following is the most likely cause of this patient's hemorrhage?
- Disseminated intravascular coagulation
 - Episiotomy site bleeding
 - Uterine atony
 - Uterine infection
 - Uterine rupture
15. A 19-year-old primigravid woman at 8 weeks' gestation is brought to the emergency department because of light vaginal bleeding and mild lower abdominal cramps during the past 8 hours. Her temperature is 37°C (98.6°F), pulse is 84/min, respirations are 18/min, and blood pressure is 110/70 mm Hg. Abdominal examination shows no tenderness or masses; bowel sounds are normal. On pelvic examination, there is old blood in the vaginal vault and at the closed cervical os. The uterus is consistent in size with a 6- to 8-week gestation. Transvaginal ultrasonography shows an intrauterine pregnancy. A fetal heartbeat is seen. Which of the following is the most appropriate next step in management?
- Discharge home for observation
 - Oral administration of misoprostol
 - Intramuscular administration of methotrexate
 - Operative laparoscopy
 - Dilatation and curettage
16. A 16-year-old girl is brought to the emergency department 6 hours after the onset of moderate lower abdominal cramps and intermittent nausea. She has not vomited during this time. She says that her last menstrual period was 2 months ago, but she has had intermittent bleeding since then, including spotting for the past 2 days. Menarche was at the age of 15 years. Menses occur at irregular 25- to 45-day intervals. She is sexually active and uses condoms inconsistently. Her temperature is 38.1°C (100.6°F), pulse is 94/min, respirations are 22/min, and blood pressure is 120/80 mm Hg. Examination shows a soft abdomen with lower quadrant tenderness, especially on the right. Bowel sounds are normal. Pelvic examination shows scant vaginal bleeding and a palpable, tender right adnexal mass. The cervix appears normal. There is no cervical motion tenderness. Which of the following is the most appropriate next step in management?
- Complete blood count
 - Measurement of serum β -hCG concentration
 - Abdominal x-ray
 - Ceftriaxone and azithromycin therapy
 - Exploratory laparoscopy
17. A 13-year-old girl is brought to the physician because of a 1-year history of intermittent irregular vaginal bleeding; the bleeding ranges from spotting to heavier than a normal menstrual period, occurs every 2 to 8 weeks, and lasts 10 to 30 days. Examination shows a pink, well-rugated vagina with no discharge; the cervix appears normal. The uterus is 6 cm in length, regular in contour, and nontender. There are palpable, normal-sized, nontender ovaries. Which of the following is the most appropriate pharmacotherapy to alleviate this patient's symptoms?
- Continuous low-dose estrogen
 - Gonadotropin-releasing hormone agonist
 - Oral contraceptives
 - Tetracycline
 - Thyroid hormone

18. A previously healthy 25-year-old woman, gravida 2, para 2, comes to the emergency department because of a 3-day history of painful swelling of her vaginal area. Her last menstrual period was 2 months ago. She is sexually active with one male partner and uses depot medroxyprogesterone for contraception. Her temperature is 38.4°C (101.2°F), pulse is 96/min, respirations are 16/min, and blood pressure is 125/82 mm Hg. Examination shows a 4-cm, exquisitely tender mass in the inferior aspect of the left labium minus. The swelling and tenderness prevent insertion of either a speculum or fingers into the vagina. Which of the following is the most likely diagnosis?
- (A) Bartholin gland abscess
 - (B) Chancroid
 - (C) Condylomata acuminata
 - (D) Herpes simplex
 - (E) Lymphogranuloma venereum
 - (F) Primary syphilis
19. A 22-year-old primigravid woman at 34 weeks' gestation is brought to the emergency department by ambulance after being found unconscious by her husband. Paramedics report that she was having tonic-clonic movements that have now stopped. Her last visit to the physician was 2 weeks ago. Pregnancy had been uncomplicated. On arrival, she is awake, lethargic, and mildly confused. She says that she had a headache and did not feel well earlier in the day. She has no history of serious illness. Her only medication is a prenatal vitamin. Her temperature is 37°C (98.6°F), pulse is 80/min, respirations are 18/min, and blood pressure is 170/110 mm Hg. Examination shows a nontender, soft uterus consistent in size with a 34-week gestation. Cranial nerves are intact. Motor function is normal. Deep tendon reflexes are 3+. Which of the following is the most likely diagnosis?
- (A) Absence seizures
 - (B) Cerebral infarction
 - (C) Eclampsia
 - (D) Migraine
 - (E) Pheochromocytoma
20. A 15-year-old girl is brought to the physician by her mother because she believes that her daughter has become sexually active and wants her to use contraception. During an interview with the patient alone, she reports that she has become sexually active with one male partner over the past 3 months. She and her partner use condoms consistently, and she is not interested in any other form of contraception at this time. Menarche was at the age of 12 years, and menses occur at regular 28-day intervals. She has had no symptoms of sexually transmitted diseases. Examination shows no abnormalities. In addition to counseling the patient about all contraceptive methods, which of the following is the most appropriate next step?
- (A) Do not inform the mother that her daughter and her partner use condoms, but encourage the daughter to communicate the information
 - (B) Inform the mother that her daughter and her partner use condoms
 - (C) Inform the mother that her daughter is protecting herself appropriately against pregnancy, but do not mention what form of contraception
 - (D) Inform the mother that you have administered depot medroxyprogesterone to the patient
 - (E) Inform the mother that you have given the patient a prescription for an oral contraceptive

Answer Form for Obstetrics and Gynecology Sample Questions

(Questions 1-20)

- | | |
|-----------|-----------|
| 1. _____ | 11. _____ |
| 2. _____ | 12. _____ |
| 3. _____ | 13. _____ |
| 4. _____ | 14. _____ |
| 5. _____ | 15. _____ |
| 6. _____ | 16. _____ |
| 7. _____ | 17. _____ |
| 8. _____ | 18. _____ |
| 9. _____ | 19. _____ |
| 10. _____ | 20. _____ |

Answer Key for Obstetrics and Gynecology Sample Questions

(Questions 1-20)

- | | | | |
|-----|---|-----|---|
| 1. | B | 11. | A |
| 2. | B | 12. | D |
| 3. | B | 13. | F |
| 4. | D | 14. | C |
| 5. | B | 15. | A |
| 6. | C | 16. | B |
| 7. | B | 17. | C |
| 8. | A | 18. | A |
| 9. | E | 19. | C |
| 10. | C | 20. | A |

PEDIATRICS

<i>Normal Development</i>	5%–10%
<i>Organ Systems</i>	90%–95%
Immunologic Disorders	5%–10%
Diseases of the Blood and Blood-forming Organs	5%–10%
Mental Disorders	1%–5%
Diseases of the Nervous System and Special Senses	5%–10%
Cardiovascular Disorders	10%–15%
Diseases of the Respiratory System	10%–15%
Nutritional and Digestive Disorders	10%–15%
Gynecologic Disorders	1%–5%
Renal, Urinary, and Male Reproductive System	10%–15%
Disorders of Pregnancy, Childbirth, and the Puerperium	1%–5%
Disorders of the Skin and Subcutaneous Tissues	1%–5%
Diseases of the Musculoskeletal System and Connective Tissue	5%–10%
Endocrine and Metabolic Disorders	5%–10%
<i>Physician Tasks</i>	
Promoting Health and Health Maintenance	5%–10%
Understanding Mechanisms of Disease	25%–30%
Establishing a Diagnosis	40%–45%
Applying Principles of Management	10%–15%

- (A) Ankyloglossia (tongue-tie)
- (B) Attention-deficit/hyperactivity disorder
- (C) Autistic disorder
- (D) Hearing loss
- (E) Neurodegenerative disorder
- (F) Normal language development
- (G) Mental retardation
- (H) Parental neglect
- (I) Selective mutism
- (J) Serous otitis media

For each child brought for a well-child examination, select the most likely diagnosis.

1. A 4-year-old boy squeals and cries but uses no words. His gross and fine motor skills are well developed. He is preoccupied with objects and does not play with other children. The child responds normally to sounds but appears disinterested and detached.
2. A 16-month-old infant babbled at 6 months, began to mimic sounds at 10 months, and began to use a few recognizable words between 12 and 14 months. At 16 months, the child is continuing to use single words but is not using simple two-word phrases.

3. A 2-month-old infant has a 5-cm strawberry hemangioma on the cheek that is increasing in size. No other lesions are noted. Which of the following is the most appropriate next step in management?
- Observation of the lesion
 - Solid carbon dioxide application to the lesion
 - Intralesional corticosteroid treatment
 - Laser therapy to the lesion
 - Surgical removal of the lesion
4. A previously healthy 15-year-old girl comes to the physician because of increasing left ear pain during the past 3 days. Vital signs are within normal limits. Examination of the left ear shows edema and erythema of the auditory canal with a greenish discharge. Manipulation of the left pinna elicits pain. The tympanic membrane can only partially be visualized, and examination of what can be seen appears normal with normal mobility. Examination of the right ear shows no abnormalities. Which of the following is the most likely diagnosis?
- Acute otitis media
 - Furunculosis
 - Mastoiditis
 - Otitis externa
 - Tympanic membrane perforation
5. A 3175-g (7-lb) newborn is delivered at term to a 21-year-old woman, gravida 1, para 1. Pregnancy, labor, and delivery were uncomplicated. Examination shows ambiguous genitalia. Which of the following is the most appropriate physician response to the parents regarding their newborn's gender?
- "The decision about your child's gender is entirely yours."
 - "You have a beautiful new daughter."
 - "Your baby is a boy, but his genitals are not yet fully developed."
 - "Your baby looks healthy, but we will not know the gender until we run additional tests."
6. One week after a "breathing treatment" in the emergency department for an initial episode of coughing and wheezing, a 10-year-old girl is brought to the physician for a follow-up examination. She has a 3-year history of nasal allergies; both her parents have allergic rhinitis. She is afebrile. The lungs are clear to auscultation. An x-ray of the chest shows normal findings. Which of the following medications is most appropriate on an as-needed basis?
- Inhaled β -adrenergic agonist
 - Inhaled corticosteroids
 - Inhaled cromolyn sodium
 - Oral β -adrenergic agonist
 - Oral theophylline
7. A 4-year-old boy is brought to the physician by his parents because of a 2-month history of difficulty sleeping. His parents report that he typically awakens 1 hour after going to sleep and cries loudly. When his parents come to his room, he appears frightened and is unaware of their attempts to comfort him. In the morning, he has no memory of these episodes. Physical examination shows no abnormalities. Which of the following is the most likely diagnosis?
- Factitious disorder
 - Oppositional defiant disorder
 - Seizure disorder
 - Separation anxiety disorder
 - Sleep terror disorder
8. A male newborn is born to a 32-year-old woman by cesarean delivery at 38 weeks' gestation and weighs 4309 g (9 lb 8 oz). The pregnancy was complicated by gestational diabetes that was difficult to manage. Apgar scores are 6 and 8 at 1 and 5 minutes, respectively. This newborn is at increased risk for developing which of the following within the next 24 hours?
- Hypercalcemia
 - Hyperglycemia
 - Hyperkalemia
 - Hypoglycemia
 - Hypokalemia
 - Hypothermia
9. A 14-year-old girl is brought to the physician for a well-child examination. She reports that she occasionally feels sad because "everyone else is confident except me." She notes that she likes a new boy in her class, but she is afraid that "he doesn't know that I exist." She sometimes worries that she will attract his attention, but this is not a constant worry. She adds, "I know he likes this really pretty singer on TV, and I could never measure up to her. I am not sure that anyone can really relate to my situation." She generally gets along well with friends and family. She is in the eighth grade and maintains a B average. She plays on the school soccer team and is an active member of the Girl Scouts. She does not drink alcohol or use illicit drugs. She is not sexually active. She is at the 60th percentile for height and 50th percentile for weight. She is casually dressed. Physical examination shows no abnormalities. On mental status examination, she is cooperative with a mildly anxious mood and a full range of affect. She says she is not depressed. Which of the following is the most likely diagnosis?
- Generalized anxiety disorder
 - Histrionic personality disorder
 - Major depressive disorder
 - Narcissistic personality disorder
 - Normal development

10. A previously healthy 6-year-old boy is brought to the physician because of a 1-week history of right knee pain and swelling. He also has had occasional chills and muscle pain for 1 week. He went camping with his father in eastern Pennsylvania approximately 2 months ago. Two weeks after the trip, he had a solid red rash that slowly spread over most of his right thigh and resolved spontaneously 2 weeks later. Examination of the right knee shows swelling, an effusion, and mild tenderness to palpation. Which of the following is most likely to confirm the diagnosis?
- (A) Complete blood count
 - (B) Determination of erythrocyte sedimentation rate
 - (C) Serum antinuclear antibody assay
 - (D) Serum Lyme (*Borrelia burgdorferi*) antibody assay
 - (E) Serum rheumatoid factor assay
 - (F) X-ray of the right knee
11. An 8-year-old boy is brought to the physician by his mother for a well-child examination. His mother reports that she is exhausted because he is constantly “on the go,” is increasingly difficult to manage, and needs constant supervision. Last week, he climbed out on the roof of their house “just to see how high up it was.” He has had trouble maintaining friendships because he is “bossy” and easily frustrated if he does not win at games. His mother says that he wakes up cheerful and full of energy each morning and that he says he will “really try to be good.” His teacher usually calls by noon to report about his difficult behavior. He is disruptive in class and often “plays the class clown.” When asked to sit still and do his work, he becomes frustrated and shouts, “I can’t sit still.” He is unable to work quietly for more than 15 minutes. The school has threatened to suspend him if his behavior does not improve. His grades are poor. He is at the 70th percentile for height and 45th percentile for weight. Vital signs are within normal limits. Physical examination shows no abnormalities. During the examination, he is cheerful and verbally impulsive. After the examination, his mother becomes tearful and says she does not know what to do. Which of the following is the most appropriate initial response?
- (A) “Clearly he needs medication right away.”
 - (B) “I think that the school is being unfair to your child.”
 - (C) “It certainly sounds as though things have been difficult for you.”
 - (D) “You should look into other schools to give him a fresh start.”
 - (E) “You should see a therapist to talk about your feelings.”
12. A previously healthy 10-year-old boy is brought to the emergency department by his parents immediately after the sudden onset of difficulty breathing that began when he was stung on the arm by a bee. On arrival, he is in severe respiratory distress. His temperature is 38°C (100.4°F), pulse is 115/min, respirations are 60/min, and blood pressure is 80/40 mm Hg. Examination shows supraclavicular and intercostal retractions. There is diffuse urticaria over the trunk and upper and lower extremities. Expiratory wheezes are heard bilaterally. Which of the following is the most appropriate initial pharmacotherapy?
- (A) Oral diphenhydramine
 - (B) Inhaled fluticasone
 - (C) Subcutaneous epinephrine
 - (D) Intravenous methylprednisolone
 - (E) Intravenous ranitidine
13. A 16-year-old girl is brought to the physician because of severe acne over her face and upper back for 6 months. She has had no itching or scaling of the acne. Treatment with topical and oral antibiotics has not resolved her symptoms. Examination shows numerous papules and pustules with widespread erythema over the face and upper back. There is no hyperpigmentation. The patient requests information about beginning isotretinoin, because she says it improved her boyfriend’s acne. Which of the following is the most appropriate initial step prior to treatment with isotretinoin?
- (A) Complete blood count with differential
 - (B) Determination of prothrombin and partial thromboplastin times
 - (C) 24-Hour urine collection for measurement of creatinine clearance
 - (D) Measurement of serum thyroid-stimulating hormone concentration
 - (E) Measurement of urine β -hCG concentration
 - (F) PPD skin test
14. A 3-year-old girl is brought to the emergency department 2 days after the onset of fever, profuse watery diarrhea, and progressive lethargy. On arrival, she appears ill and is poorly responsive. Her temperature is 39.4°C (103°F), pulse is 180/min, respirations are 40/min, and blood pressure is 80/45 mm Hg. Examination shows poor skin turgor and cool extremities. Mucous membranes are dry. Capillary refill time is delayed. Which of the following is the most appropriate next step to decrease the risk of acute renal failure in this patient?
- (A) Monitoring urine output
 - (B) Ceftriaxone therapy
 - (C) Diuretic therapy
 - (D) Fluid resuscitation
 - (E) Vasopressor therapy

15. A 3-year-old girl with Down syndrome is brought to the physician because of a 1-week history of frequent nosebleeds, decreased appetite, and lethargy. She takes no medications. Her temperature is 38°C (100.4°F), pulse is 100/min, respirations are 20/min, and blood pressure is 80/45 mm Hg. Examination shows no other abnormalities except for pallor. Laboratory studies show:

Hemoglobin	6.5 g/dL
Hematocrit	19%
Leukocyte count	100,000/mm ³
Segmented neutrophils	15%
Atypical lymphocytes	85%
Platelet count	45,000/mm ³

Which of the following is the most likely mechanism of these laboratory findings?

- (A) Bone marrow hypoplasia
- (B) Infiltration of bone marrow by leukemic blasts
- (C) Iron deficiency
- (D) Lymphocyte inhibitors of erythropoiesis
- (E) Reticuloendothelial phagocytosis of platelets
- (F) Serum immunoglobulin A deficiency

16. A 16-year-old girl is brought to the physician for a school physical examination. She has no history of serious illness and takes no medications. Menarche has not yet occurred. She is 155 cm (5 ft 1 in) tall and weighs 66 kg (145 lb); BMI is 27 kg/m². Her blood pressure is 140/80 mm Hg in the left arm and 105/70 mm Hg in the left leg. Vital signs are otherwise within normal limits. A grade 2/6 systolic murmur is heard best over the upper back to the left of the midline. The extremities are well perfused with strong peripheral pulses. Breast development is Tanner stage 2, and pubic hair development is Tanner stage 1. This patient most likely has an abnormality of which of the following vessels?

- (A) Aorta
- (B) Coronary artery
- (C) Pulmonary artery
- (D) Renal artery
- (E) Renal vein

17. An 11-year-old girl with cystic fibrosis is admitted to the hospital 18 hours after the onset of shortness of breath. During the past 11 years, she has had more than 20 episodes of respiratory exacerbations of her cystic fibrosis that have required hospitalization. Current medications include an inhaled bronchodilator, inhaled corticosteroid, oral pancreatic enzyme, and oral multivitamin. Her temperature is 38°C (100.4°F), pulse is 96/min, respirations are 28/min, and blood pressure is 92/68 mm Hg. Diffuse wheezes and crackles are heard bilaterally. A sputum culture grows *Burkholderia cepacia*. Which of the following is the most likely cause of this patient's recurrent respiratory tract infections?

- (A) Immune suppression
- (B) Impaired clearing of airway secretions
- (C) Increased exposure to infectious organisms
- (D) Interstitial fibrosis
- (E) Restrictive changes of the small airways

18. A 3-week-old infant is brought to the physician by his mother because of a 1-week history of increasingly frequent vomiting. She says that at first he vomited occasionally, but now he vomits after every feeding. The vomitus is nonbilious and consists of breast milk. He has had fewer wet diapers during the past 2 days. He was born at term following an uncomplicated pregnancy and initially fed well. He appears lethargic and dehydrated. A 1 × 2-cm, firm, mobile, olive-shaped mass is palpated immediately to the left of the epigastrium. Which of the following is the most likely diagnosis?

- (A) Congenital megacolon (Hirschsprung disease)
- (B) Duodenal atresia
- (C) Intussusception
- (D) Midgut volvulus
- (E) Pyloric stenosis

19. A 15-year-old girl is brought to the physician by her mother because of a 1-year history of monthly cramps that begin 2 days before menses and last 3 days. The cramps have increased in severity during the past 6 months. She is unable to practice with her volleyball team because of the pain and typically misses 2 days of school monthly. Menarche was at the age of 12 years. Menses occur at regular 30-day intervals and last 4 days with normal flow. She has no history of serious illness and takes no medications. She has never been sexually active. Physical examination shows no abnormalities. Which of the following is the most likely cause of this patient's pain?

- (A) Bladder wall permeability
- (B) Degenerating myoma
- (C) Endometrial prostaglandin production
- (D) *Escherichia coli* infection
- (E) Intestinal hypermobility

20. A 5-year-old girl is brought to the physician by her parents for evaluation of recurrent injuries. Her parents say that she started walking at the age of 14 months and since then has always seemed clumsier and had more injuries than other children. She has had increasingly frequent pain with exertion since starting a soccer program 3 months ago. She usually has pain or swelling of her knees or ankles after practice. She has been taken to the emergency department three times during the past 3 weeks because of concern about possible fractures; x-rays showed no abnormalities. Today, the patient walks with a limp. Examination shows numerous paper-like scars over the torso and upper and lower extremities. A midsystolic click is heard at the apex. The left ankle is swollen and tender; range of motion is limited by pain. The hips and the joints of the upper and lower extremities are hypermobile, including 25 degrees of genu recurvatum, thumbs that may be extended to touch the forearms, and flexibility at the waist, with palms easily touching the floor with straight knees. Which of the following is the most likely explanation for this patient's physical findings?
- (A) Cerebellar degeneration
 - (B) Collagen abnormality
 - (C) Complement deficiency
 - (D) Defect in the migration of segmented neutrophils
 - (E) Immune complex deposition
 - (F) Vitamin D deficiency

Answer Form for Pediatrics Sample Questions

(Questions 1-20)

1. _____
2. _____
3. _____
4. _____
5. _____
6. _____
7. _____
8. _____
9. _____
10. _____

11. _____
12. _____
13. _____
14. _____
15. _____
16. _____
17. _____
18. _____
19. _____
20. _____

Answer Key for Pediatrics Sample Questions

(Questions 1-20)

- | | | | |
|-----|---|-----|---|
| 1. | C | 11. | C |
| 2. | F | 12. | C |
| 3. | A | 13. | E |
| 4. | D | 14. | D |
| 5. | D | 15. | B |
| 6. | A | 16. | A |
| 7. | E | 17. | B |
| 8. | D | 18. | E |
| 9. | E | 19. | C |
| 10. | D | 20. | B |

PSYCHIATRY

<i>General Principles</i>	5%–10%
<i>Organ Systems</i>	90%–95%
Mental Disorders	75%–85%
Mental disorders usually first diagnosed in infancy, childhood, or adolescence	
Substance-related disorders	
Schizophrenia and other psychotic disorders	
Mood disorders	
Anxiety disorders	
Somatoform disorders	
Other disorders/conditions	
Diseases of the Nervous System and Special Senses	10%–20%
<i>Physician Tasks</i>	
Promoting Health and Health Maintenance	1%–5%
Understanding Mechanisms of Disease	10%–15%
Establishing a Diagnosis	55%–65%
Applying Principles of Management	15%–20%

1. A 3-year-old girl is brought to the physician by her parents because they are concerned about her behavior. They describe their daughter as stubborn and always on the go. She can rarely sit still for more than 10 minutes. She often refuses to comply with their requests and sometimes throws 3- to 5-minute temper tantrums. They report that she dawdles at bedtime and requires frequent direction and assistance in preparing for bed. Her preschool teacher notes that she is active and talkative without being disruptive and is beginning to demonstrate more interactive play with her peers. She generally sleeps through the night and occasionally wets the bed. Her appetite is good. Her first word was at the age of 11 months, and she began walking without assistance at the age of 14 months. Physical examination shows no abnormalities. On mental status examination, she initially hides behind her mother but warms to the interviewer after a few minutes and begins playing with toys in the office. Her speech is 90% intelligible, and her vocabulary is large for her age. Which of the following is the most appropriate next step in management?

 - (A) Reassurance
 - (B) Play therapy
 - (C) Speech therapy
 - (D) Enuresis alarm
 - (E) Trial of fluoxetine
 - (F) Trial of methylphenidate
2. A 45-year-old man is brought to the physician by his spouse. He has been drinking heavily since he was passed over for a job promotion 3 days ago. He stayed in bed over the weekend. He has no personal history of psychiatric disorders and no personal or family history of alcohol abuse. He is crying and states, "I can't believe it," when addressed. When asked what he will do, he states, "I don't know, but if I don't go back to work tomorrow, I'll lose my job." Which of the following is the most likely diagnosis?

 - (A) Adjustment disorder with depressed mood
 - (B) Bipolar disorder
 - (C) Dysthymic disorder
 - (D) Major depressive disorder
 - (E) Substance abuse
3. A previously healthy 18-year-old woman is brought to the physician for evaluation because of loss of appetite, sleeplessness, and extreme irritability for 3 weeks. After missing many practices, she quit the college softball team that she previously enjoyed. She often feels tired and has difficulty sitting still and concentrating on schoolwork. Her menses occur at regular intervals. She weighs 50 kg (110 lb) and is 168 cm (5 ft 6 in) tall; her BMI is 18 kg/m². Her pulse is 74/min, respirations are 16/min, and blood pressure is 110/70 mm Hg. Which of the following is the most likely diagnosis?

 - (A) Adjustment disorder with mixed disturbance of emotions and conduct
 - (B) Anorexia nervosa
 - (C) Attention-deficit/hyperactivity disorder
 - (D) Dysthymic disorder
 - (E) Major depressive disorder

4. A 57-year-old man comes to the physician accompanied by his wife because of a 2-year history of fatigue. He reports waking up tired nearly every morning, often with a headache. He naps almost every afternoon. He thinks that the fatigue is affecting his concentration and performance at work. His wife says that he snores frequently during the night and sometimes wakes up gasping for air. She describes him as a restless sleeper. His tonsils and adenoids were removed when he was a child. He has no history of serious illness and takes no medications. He is 178 cm (5 ft 10 in) tall and weighs 115 kg (253 lb); BMI is 36 kg/m². His pulse is 86/min, and blood pressure is 164/88 mm Hg. The nasal septum is at the midline. Examination shows no other abnormalities. Which of the following is the most likely diagnosis?
- (A) Chronic fatigue syndrome
 - (B) Narcolepsy
 - (C) REM sleep behavior disorder
 - (D) Restless legs syndrome
 - (E) Sleep apnea
5. A 52-year-old woman whose husband died 2 months ago consults a physician because of headaches and feelings of uncertainty. She describes the headaches as a band around her head; they occur unpredictably and are not accompanied by any other symptoms. She has no history of psychiatric illness. While talking with the physician, the patient begins to cry and talk about her deceased husband; she feels her life is empty now and worries about her future. Which of the following is most appropriate at this point?
- (A) Allow her to express herself
 - (B) Prescribe an anti-anxiety drug
 - (C) Prescribe an antidepressant drug
 - (D) Refer her for psychological testing
 - (E) Obtain a psychiatric consultation
6. A 47-year-old man is brought to the emergency department by police after he was found eating garbage from a dumpster behind a restaurant. He says that he just came to this town and that he is homeless, so he has no money for food. He admits to several psychiatric hospitalizations in the past but says that he no longer needs medication. He appears dirty and is malodorous. Vital signs are within normal limits. Physical examination shows no abnormalities. On mental status examination, his speech is clear, but his thought process is disorganized with many loose associations. At several times during the interview, he appears to be preoccupied with internal stimuli. He says that he hears voices having an ongoing conversation in his head. Which of the following is the most likely diagnosis?
- (A) Bipolar disorder
 - (B) Brief psychotic disorder
 - (C) Delusional disorder
 - (D) Major depressive disorder with psychotic features
 - (E) Psychotic disorder due to a general medical condition
 - (F) Schizophrenia
 - (G) Schizotypal personality disorder
7. A 32-year-old woman is brought to the emergency department because of fever, hallucinations, agitation, and confusion for 8 hours. She has a history of alcohol, cocaine, and benzodiazepine abuse. Her temperature is 37.8°C (100°F), pulse is 110/min, respirations are 16/min, and blood pressure is 150/90 mm Hg. Examination shows tremors and telangiectasia. The lungs are clear to auscultation. There is a holosystolic murmur; the abdomen is tender, and the liver edge is palpable 3 cm below the right costal margin. Rectal examination shows no abnormalities. Her serum alkaline phosphatase activity is 200 U/L, serum ALT activity is 60 U/L, and serum AST activity is 90 U/L. Which of the following is the most likely cause of this condition?
- (A) Acute cocaine toxicity
 - (B) Alcohol withdrawal
 - (C) Benzodiazepine withdrawal
 - (D) Panic disorder
 - (E) Schizophreniform disorder
8. A 10-year-old boy is brought to the physician because of increasing behavior problems in school since starting 5th grade 3 months ago. His teacher states that he is unable to sit quietly through a classroom period and frequently disrupts the class and interrupts other children while they are talking. His parents report that he has always been an active child and are concerned because he is inattentive when he runs or walks. During examination, he fidgets with his hands and feet and is easily distracted from completing a task. Which of the following is the most appropriate pharmacotherapy?
- (A) Amitriptyline
 - (B) Fluoxetine
 - (C) Haloperidol
 - (D) Imipramine
 - (E) Methylphenidate
9. A 27-year-old woman is brought to the emergency department 1 hour after a friend found her barely arousable in her disorderly apartment with a nearly starving cat. The patient appears extremely thin. Her pulse is 90/min, respirations are 6/min, and blood pressure is 90/60 mm Hg. Physical examination shows small pupils, cracked lips, and bruises and scratches over the upper extremities. Mental status examination shows mild obtundation, blunted affect, and slow, incoherent speech. Which of the following is the most appropriate next step in management?
- (A) Observation in a quiet darkened room
 - (B) Oral administration of chlorpromazine
 - (C) Intramuscular administration of naloxone
 - (D) Intravenous administration of haloperidol
 - (E) Intravenous administration of lorazepam

10. A healthy 9-year-old boy is brought to the physician by his parents because they are concerned that he dislikes attending school. Every morning he cries and begs to stay home. He misses school at least 1 day weekly because his mother is exhausted from fighting with him to attend. His teachers report that he is quiet in class and rarely participates. He has difficulty reading at the level of his peers and lacks confidence. At home, he tends to stay in the same room as his mother and will sometimes follow her around the house. When his parents plan an evening out, he often becomes tearful and asks many questions about when they will return. He likes to have friends over to his house and appears to enjoy being with them. Physical examination shows no abnormalities. During the examination, he sits on his mother's lap and is quiet but cooperative. He makes brief eye contact and speaks in a low volume, becoming tearful when questioned about being away from his mother. Which of the following is the most likely diagnosis?
- (A) Dysthymic disorder
 - (B) Mild mental retardation
 - (C) Oppositional defiant disorder
 - (D) Reading disorder
 - (E) Separation anxiety disorder
 - (F) Social phobia
11. A 47-year-old woman is brought to the physician by her husband because of bizarre behavior for 1 week. Her husband says that she makes no sense when she speaks and seems to be seeing things. She also has had difficulty sleeping for 2 months and has gained approximately 9 kg (20 lb) during the past 5 months. During this time, she has been moody and easily fatigued. He also notes that the shape of her face has become increasingly round and out of proportion with the rest of her body despite her weight gain. She has no history of psychiatric or medical illness. She is 160 cm (5 ft 3 in) tall and weighs 70 kg (155 lb); BMI is 28 kg/m². Her pulse is 98/min, respirations are 8/min, and blood pressure is 148/92 mm Hg. Physical examination shows truncal obesity and ecchymoses over the upper and lower extremities. Neurologic examination shows no focal findings. Mental status examination shows pressured speech and a disorganized thought process. There is evidence of visual and auditory hallucinations. Urine toxicology screening is negative. Which of the following is the most likely diagnosis?
- (A) Brief psychotic disorder
 - (B) Major depressive disorder with psychotic features
 - (C) Psychotic disorder due to a general medical condition
 - (D) Schizophrenia
 - (E) Schizotypal personality disorder
12. One day after admission to the hospital for agitation and hallucinations, a 19-year-old man has the onset of severe muscle stiffness that prevents him from rising out of bed. At the time of admission, treatment with haloperidol was begun. Today, he appears lethargic and diaphoretic. His temperature is 39.7°C (103.5°F), pulse is 120/min, and blood pressure is 160/110 mm Hg. Physical examination shows generalized severe rigidity of the upper extremities bilaterally. On mental status examination, he is not oriented to person, place, and time. Which of the following is the most appropriate next step in management?
- (A) Observation only
 - (B) Add fluoxetine
 - (C) Add lithium carbonate
 - (D) Discontinue haloperidol
 - (E) Increase the dosage of haloperidol
13. A 32-year-old woman comes to the physician because of a 3-week history of depressed mood. She works as a local news anchor. She says that she has always had a busy schedule, but lately she has not had her usual amount of energy and has had difficulty getting up and going to work. She describes herself as normally a "hyper" person with energy to perform multiple tasks. During the past 10 years, she has had similar episodes in which she has had depressed mood associated with a decreased energy level that makes her feel "slowed down." The episodes never last more than a few weeks. She sometimes goes through periods when she feels a surge in energy, sleeps very little, feels at the top of her mental powers, and is able to generate new ideas for the news station; these episodes never last more than 5 days. She says that she loves feeling this way and wishes the episodes would last longer. She takes no medications. She does not drink alcohol or use illicit drugs. Her temperature is 37°C (98.6°F), pulse is 70/min, and blood pressure is 125/80 mm Hg. Physical examination shows no abnormalities. Mental status examination shows a depressed mood and flat affect. Which of the following is the most likely diagnosis?
- (A) Attention-deficit/hyperactivity disorder
 - (B) Cyclothymic disorder
 - (C) Dysthymic disorder
 - (D) Major depressive disorder
 - (E) Mood disorder due to a general medical condition

14. A 77-year-old woman is brought to the emergency department by her husband because of agitation and confusion for 3 hours. He states that she has been intermittently crying out and does not appear to recognize him. A routine health maintenance examination 3 days ago showed no abnormalities except for mild memory deficits. Her current temperature is 37.8°C (100°F), pulse is 100/min, respirations are 14/min, and blood pressure is 130/60 mm Hg. Physical examination shows no abnormalities except for mild tenderness to palpation of the lower abdomen. Mental status examination shows confusion; she is oriented to person but not to time or place. Which of the following is the most appropriate next step in diagnosis?
- (A) Determination of erythrocyte sedimentation rate
 - (B) Measurement of serum alkaline phosphatase activity
 - (C) Measurement of serum folate concentration
 - (D) Urinalysis
 - (E) Western blot assay
15. A 14-year-old boy is brought to the physician by his mother after she found an unsmoked marijuana cigarette in his bedroom. The mother reports that her son has never done anything like this before. His academic performance is excellent. When interviewed alone, the patient reports that his friends heard about smoking marijuana and acquired some from their peers to find out what it was like. He adds that he has never smoked marijuana before. He requests that his teachers not be informed because they would be very disappointed if they found out. Physical examination shows no abnormalities. On mental status examination, he is pleasant and cooperative and appears remorseful. Which of the following is the most likely diagnosis?
- (A) Conduct disorder
 - (B) Marijuana abuse
 - (C) Marijuana dependence
 - (D) Parent-child relational problem
 - (E) Normal adolescence
16. An otherwise healthy 27-year-old man is referred to a cardiologist because of three episodes of severe palpitations, dull chest discomfort, and a choking sensation. The episodes occur suddenly and are associated with nausea, faintness, trembling, sweating, and tingling in the extremities; he feels as if he is dying. Within a few hours of each episode, physical examination and laboratory tests show no abnormalities. He does not abuse drugs or alcohol and has no history of interpersonal problems. Which of the following is the most likely diagnosis?
- (A) Delusional disorder
 - (B) Generalized anxiety disorder
 - (C) Hypochondriasis
 - (D) Panic disorder
 - (E) Somatization disorder
17. A 42-year-old woman is brought to the physician by her husband because of persistent sadness, apathy, and tearfulness for the past 2 months. She has a 10-year history of systemic lupus erythematosus poorly controlled with corticosteroid therapy. Physical examination shows 1-cm erythematous lesions over the upper extremities and neck and a malar butterfly rash. On mental status examination, she appears depressed. She says that she would be better off dead. Which of the following is the most appropriate next step in management?
- (A) Ask the patient about her suicidal thoughts
 - (B) Reassure the patient that she will get well
 - (C) Recommend psychiatric hospitalization
 - (D) Begin paroxetine therapy
 - (E) Increase the dose of corticosteroid
18. A 27-year-old man is brought to the emergency department by police 2 hours after threatening his next door neighbor. The neighbor called the police after receiving a note demanding that she stop videotaping all of the activities in the patient's home or he would call the police. During the examination, the patient is cooperative. He explains that he has lived in the neighborhood for 8 months. Three months ago, he noticed that his neighbor installed a new satellite dish and says that since that time, she has been watching every move he makes. He reports no personal or family history of psychiatric illness. He has not had changes in sleep pattern and performs well in his job as a car salesman. He appears neatly dressed. Physical examination shows no abnormalities. On mental status examination, his thought process is organized and logical. There is no evidence of suicidal or homicidal ideation or hallucinations. He says that he is not suspicious of anyone other than his neighbor. Which of the following is the most likely diagnosis?
- (A) Bipolar disorder
 - (B) Brief psychotic disorder
 - (C) Delusional disorder
 - (D) Major depressive disorder with psychotic features
 - (E) Schizophrenia

19. A 9-year-old girl is brought to the physician by her adoptive parents because they are concerned about her increasing difficulty at school since she began third grade 7 weeks ago. Her teachers report that she is easily frustrated and has had difficulty reading and paying attention. She also has had increased impulsivity and more difficulty than usual making and keeping friends. Her biologic mother abused multiple substances before and during pregnancy, and the patient was adopted shortly after birth. She is at the 20th percentile for height and 40th percentile for weight. Examination shows a flattened nasal bridge and a long philtrum. During the examination, she is cheerful. Psychoeducational testing shows an IQ of 82. The most likely explanation for these findings is in utero exposure to which of the following?

- (A) Alcohol
- (B) Cocaine
- (C) Ecstasy (3,4-methylenedioxymethamphetamine)
- (D) Heroin
- (E) Marijuana
- (F) PCP (phencyclidine)
- (G) Toluene

20. A 77-year-old man comes to the physician with his daughter for a follow-up examination to learn the results of neuropsychological testing performed 1 week ago for evaluation of a recent memory loss. Results of the testing indicated cognitive changes consistent with early stages of dementia. Three weeks ago, he was diagnosed with prostate cancer and has shown signs of a depressed mood since then. Twenty years ago, he required treatment in a hospital for major depressive disorder. His symptoms resolved with antidepressant therapy, and he has not taken any psychotropic medication for the past 15 years. The patient's daughter comes into the examination room before her father and asks that the physician not tell her father any information that might be upsetting, given his vulnerability to depression. She says she is concerned about what the results might be and how her father will handle them. The patient enters the room soon after his daughter makes her request. Which of the following is the most appropriate initial physician statement to this patient?

- (A) "Because of your history of depression, I would like you to start on an antidepressant medication before we talk any further about your neuropsychological testing."
- (B) "Before going over your test results, I'd like to hear how you have been doing. You have been through a difficult time."
- (C) "I would like to talk with your daughter a bit about your test results, and then I will go over things with you."
- (D) "Your daughter is concerned about you. I think you need to see a psychiatrist before we go any further here."
- (E) "Your tests were inconclusive, and I would like to have you start on a medication to help with your memory as a precaution."

Answer Form for Psychiatry Sample Questions

(Questions 1-20)

1. _____
2. _____
3. _____
4. _____
5. _____
6. _____
7. _____
8. _____
9. _____
10. _____

11. _____
12. _____
13. _____
14. _____
15. _____
16. _____
17. _____
18. _____
19. _____
20. _____

Answer Key for Psychiatry Sample Questions

(Questions 1-20)

- | | | | |
|-----|---|-----|---|
| 1. | A | 11. | C |
| 2. | A | 12. | D |
| 3. | E | 13. | B |
| 4. | E | 14. | D |
| 5. | A | 15. | E |
| 6. | F | 16. | D |
| 7. | B | 17. | A |
| 8. | E | 18. | C |
| 9. | C | 19. | A |
| 10. | E | 20. | B |

SURGERY

<i>General Principles</i>	1%–5%
<i>Organ Systems</i>	95%–99%
Immunologic Disorders	1%–5%
Diseases of the Blood and Blood-forming Organs	5%–10%
Diseases of the Nervous System and Special Senses	5%–10%
Cardiovascular Disorders	10%–15%
Diseases of the Respiratory System	10%–15%
Nutritional and Digestive Disorders	25%–30%
Gynecologic Disorders	5%–10%
Renal, Urinary, and Male Reproductive System	5%–10%
Disorders of Pregnancy, Childbirth, and the Puerperium	1%–5%
Disorders of the Skin and Subcutaneous Tissues	1%–5%
Diseases of the Musculoskeletal System and Connective Tissue	5%–10%
Endocrine and Metabolic Disorders	5%–10%
<i>Physician Tasks</i>	
Promoting Health and Health Maintenance	1%–5%
Understanding Mechanisms of Disease	20%–25%
Establishing a Diagnosis	45%–50%
Applying Principles of Management	25%–30%

1. A 52-year-old woman with glioblastoma multiforme in the frontal lobe tells her physician that she does not want operative treatment. She is mentally competent and understands that an operation is the only effective treatment of her tumor, and that without an operation she will die. She is afraid of the adverse effects of an operation and says she has lived a long and happy life. Two weeks later, she lapses into a coma, and her husband requests that the operation be carried out. Which of the following is the most appropriate consideration for her physician in deciding whether to operate?
 - (A) Her age
 - (B) Her husband's request
 - (C) Her previously expressed wishes
 - (D) Her quality of life
 - (E) Medical indications for treatment
2. Ten years ago, a 60-year-old woman underwent an aortic valve replacement with a porcine heterograft. She now has shortness of breath with exertion. Examination and x-ray of the chest show evidence of congestive heart failure. Which of the following is the most likely explanation for these findings?
 - (A) Degeneration of the valve
 - (B) Development of an ascending aortic aneurysm
 - (C) Development of mitral stenosis
 - (D) Development of a ventricular septal defect
 - (E) Embolus to the coronary circulation
3. A 42-year-old woman comes to the emergency department because of a 2-day history of intermittent lower abdominal pain and nausea and vomiting. She has not passed flatus or stool during this time. She describes the pain as waxing and waning. Initially, the vomitus was food that she had recently eaten, but it is now bilious; there has been no blood in the vomit. She underwent a hysterectomy 2 years ago for leiomyomata uteri. Vital signs are within normal limits. Examination shows a distended tympanic abdomen with diffuse tenderness and no rebound. Bowel sounds are initially quiet but then become loud with the onset of pain. Abdominal x-rays show distended loops of bowel with air-fluid levels. Which of the following is the most likely mechanism of this patient's symptoms?
 - (A) Chronic postoperative infection
 - (B) Immunologic damage to the bowel wall due to exposure to occult antigens during the operation
 - (C) Inflammatory reaction to suture material left inside the abdomen
 - (D) Mechanical obstruction from implantation of leiomyomata uteri
 - (E) Proliferation of fibroblasts forming scar tissue in the area of the operation

4. A 4-year-old boy is brought to the physician by his parents because of a 4-month history of difficulty running and frequent falls. His parents report that his calves have been gradually increasing in size during this period. Examination shows diffusely enlarged muscles of the calves and lumbar lordosis. Sensation is intact. He has difficulty arising from a supine position. Which of the following is the most likely diagnosis?
- (A) Duchenne muscular dystrophy
 - (B) Juvenile idiopathic arthritis
 - (C) Lumbosacral radiculopathy
 - (D) Rhabdomyosarcoma
 - (E) Spina bifida
5. An 18-year-old man is brought to the emergency department 10 minutes after he sustained a stab wound to his chest. On arrival, he is unresponsive to painful stimuli. His pulse is 130/min, respirations are 8/min and shallow, and palpable systolic blood pressure is 60 mm Hg. He is intubated and mechanically ventilated, and infusion of 0.9% saline is begun. After 5 minutes, his pulse is 130/min, and blood pressure is 70/40 mm Hg. Examination shows a 2-cm wound at the left sixth intercostal space at the midclavicular line. There is jugular venous distention. Breath sounds are normal. The trachea is at the midline. Heart sounds are not audible. Which of the following is the most likely cause of these findings?
- (A) Bronchial disruption
 - (B) Hemothorax
 - (C) Myocardial infarction
 - (D) Pericardial tamponade
 - (E) Tension pneumothorax
6. A 70-year-old man is admitted to the hospital for elective coronary artery bypass grafting. On the day of his operation, an asymptomatic carotid bruit is found. Which of the following is the most appropriate immediate next step in diagnosis?
- (A) Duplex scan of the neck
 - (B) CT scan of the head
 - (C) PET scan of the brain
 - (D) MRI of the brain
 - (E) Cerebral angiography
7. Ten days after admission to the hospital because of acute pancreatitis, a 56-year-old man with alcoholism develops chills and temperatures to 39.4°C (103°F). Examination shows a tender abdomen with hypoactive bowel sounds. Which of the following is the most likely diagnosis?
- (A) Pancreatic abscess
 - (B) Pancreatic insufficiency
 - (C) Perforated duodenal ulcer
 - (D) Retroperitoneal hemorrhage
 - (E) Splenic vein thrombosis
8. A 24-year-old nulligravid woman is brought to the emergency department after a syncopal episode at work. She has had progressively severe cramps in the lower abdomen over the past 6 hours. She has had spotty vaginal bleeding for 2 days; her last menstrual period began 7 weeks ago. She is diaphoretic and anxious. Her temperature is 37°C (98.6°F), pulse is 130/min, respirations are 26/min, and blood pressure is 80/60 mm Hg. Examination shows blood in the vaginal vault and diffuse abdominal tenderness; there is pain with cervical motion. Which of the following is the most appropriate next step in management?
- (A) Intravenous administration of fluids
 - (B) Intravenous administration of broad-spectrum antibiotics
 - (C) Transfusion of O-negative blood
 - (D) Transfusion of type-specific blood
 - (E) Culdocentesis
9. A 52-year-old man comes to the physician because of a 5-month history of pain in his left knee that is exacerbated by walking long distances. There is no history of trauma. He has hypertension well controlled with enalapril. His job does not require carrying heavy loads. He is 180 cm (5 ft 11 in) tall and weighs 95 kg (210 lb); BMI is 29 kg/m². His pulse is 82/min and regular, respirations are 16/min, and blood pressure is 130/82 mm Hg. Examination of the left knee shows mild crepitus with flexion and extension; there is no effusion or warmth. X-rays of the knees show narrowing of the joint space in the left knee compared with the right knee. Which of the following is most likely to improve this patient's symptoms?
- (A) High-impact aerobics program
 - (B) Weight loss program
 - (C) Daily colchicine prophylaxis
 - (D) Daily shark cartilage supplementation
 - (E) Daily vitamin D supplementation
10. A previously healthy 32-year-old man comes to the emergency department because of a 3-day history of pain and swelling of his right knee. Two weeks ago, he injured his right knee during a touch football game and has had swelling and bruising for 5 days. One week ago, he underwent extraction of a molar for severe dental caries. He is sexually active with one male partner and uses condoms consistently. HIV antibody testing was negative 3 months ago. His temperature is 38.6°C (101.5°F), pulse is 100/min, and blood pressure is 120/60 mm Hg. Examination of the right knee shows warmth, erythema, and a joint effusion. Flexion and extension of the right knee are severely limited. An x-ray of the knee confirms the joint effusion. Which of the following is the most appropriate next step in diagnosis?
- (A) Venous Doppler ultrasonography
 - (B) Bone scan
 - (C) MRI of the knee
 - (D) Arthroscopic exploration of the knee
 - (E) Arthrocentesis

11. A 57-year-old woman with inoperable small cell carcinoma of the lung has had lethargy, loss of appetite, and nausea for 1 week. She received radiation therapy 2½ years ago. She has stable angina pectoris controlled with nitrates. Her pulse is 68/min, respirations are 16/min, and blood pressure is 118/72 mm Hg. There is no jugular venous distention, and skin turgor is normal. She is oriented to person and place but not to time. Laboratory studies show:

Serum	
Na ⁺	128 mEq/L
Cl ⁻	100 mEq/L
K ⁺	4.2 mEq/L
HCO ₃ ⁻	24 mEq/L
Urea nitrogen	11 mg/dL
Glucose	92 mg/dL
Creatinine	0.8 mg/dL
Osmolality	270 mOsmol/kg H ₂ O
Urine	
Na ⁺	78 mEq/L
Osmolality	310 mOsmol/kg H ₂ O

An x-ray of the chest shows a mass in the right upper lobe of the lung that is unchanged from an x-ray taken 3 months ago. Which of the following is the most likely explanation for these findings?

- (A) Compulsive water drinking
- (B) Congestive heart failure
- (C) Hypothyroidism
- (D) Surreptitious use of diuretics
- (E) Syndrome of inappropriate secretion of ADH (vasopressin)

12. A 3799-g (8-lb 6-oz) female newborn is born by cesarean delivery because of a breech presentation. Apgar scores are 7 and 9 at 1 and 5 minutes, respectively. Initial examination shows a palpable clunk when the left hip is abducted, flexed, and lifted forward. Posterior pressure on the flexed hip elicits a similar clunk. The remainder of the examination shows no abnormalities. Which of the following is the most likely diagnosis?
- (A) Congenital hip dysplasia
 - (B) Legg-Calvé-Perthes disease
 - (C) Osgood-Schlatter disease
 - (D) Osteogenesis imperfecta
 - (E) Slipped capital femoral epiphysis
13. A previously healthy 72-year-old man comes to the physician because of decreased urinary output during the past 2 days; he has had no urinary output for 8 hours. Examination shows suprapubic fullness and an enlarged prostate. His serum urea nitrogen concentration is 88 mg/dL, and serum creatinine concentration is 3.5 mg/dL. Which of the following is the most appropriate next step in management?
- (A) Ultrasonography of the prostate
 - (B) Ultrasonography of the kidneys
 - (C) CT scan of the abdomen
 - (D) Bladder catheterization
 - (E) Intravenous pyelography
14. A 3-year-old boy is brought to the emergency department because of a 2-week history of persistent cough and wheezing. His mother states that his symptoms occur when he laughs or runs. He has not had any other symptoms, and no one else at home is sick. Three weeks ago, he had an episode of choking and coughing while eating dinner. His temperature is 37.6°C (99.7°F), pulse is 90/min, respirations are 20/min, and blood pressure is 70/45 mm Hg. Expiratory wheezes are heard on the right with normal airflow. The remainder of the examination shows no abnormalities. His symptoms do not improve after administration of nebulized albuterol. An expiratory chest x-ray shows hyperinflation of the right lung; there is no mediastinal or tracheal shift. Which of the following is the most likely diagnosis?
- (A) Asthma
 - (B) Foreign body aspiration
 - (C) Laryngotracheobronchitis (croup)
 - (D) Psychogenic cough
 - (E) Tension pneumothorax
15. Two hours after undergoing a right hepatic lobectomy, a 59-year-old woman has a distended abdomen. Her pulse is 120/min, and blood pressure is 100/60 mm Hg. Which of the following is the most likely cause of these findings?
- (A) Deficiency of factor III
 - (B) Deficiency of factor VII
 - (C) Deficiency of factor XII
 - (D) Deficiency of platelets
 - (E) Poor mechanical hemostasis

16. Three days after undergoing elective laparoscopic cholecystectomy for cholelithiasis, a 42-year-old woman has the onset of hematomas at all surgical sites. She was treated for deep venous thrombosis 3 years ago but was not taking any medications at the time of this admission. Results of preoperative laboratory studies were within the reference range. Prior to the operation, she received heparin and underwent application of compression stockings. Her initial postoperative course was uncomplicated. Her only medication is ibuprofen. She is 163 cm (5 ft 4 in) tall and weighs 87 kg (192 lb); BMI is 33 kg/m². Her temperature is 37.3°C (99.2°F), pulse is 94/min, respirations are 16/min, and blood pressure is 112/74 mm Hg. Examination shows mild hematomas at all surgical sites. The abdomen is soft and nontender. There is no organomegaly. Bowel sounds are normal. Laboratory studies show:

Hemoglobin	10.3 g/dL
Hematocrit	30%
Leukocyte count	12,000/mm ³
Platelet count	45,000/mm ³

Which of the following is the most likely cause of this patient's current findings?

- (A) Acute intermittent porphyria
- (B) Heparin-induced thrombocytopenia
- (C) Hypersplenism
- (D) Inhibition of cyclooxygenase
- (E) von Willebrand disease

17. Two days after undergoing surgical repair of a ruptured abdominal aortic aneurysm, a 67-year-old man requires increasing ventilatory support. He remains intubated and is being mechanically ventilated at an FIO₂ of 0.6 and a positive end-expiratory pressure of 7.5 cm H₂O. He has chronic obstructive pulmonary disease. He had a myocardial infarction 2 years ago. His only medication is a sedative. He has smoked two packs of cigarettes daily for 40 years. He appears diaphoretic. His temperature is 38.1°C (100.6°F), pulse is 120/min, and blood pressure is 90/60 mm Hg; the ventilatory rate is 25/min. Examination shows jugular venous distention. Breath sounds are absent on the left. The trachea is shifted to the right. Pulse oximetry shows an oxygen saturation of 82%. Which of the following is the most appropriate next step in diagnosis?

- (A) ECG
- (B) Transthoracic echocardiography
- (C) CT scan of the chest
- (D) Needle aspiration of the left side of the chest

18. A previously healthy 62-year-old man comes to the physician because of a 2-month history of cough. He has smoked two packs of cigarettes daily for 40 years. Examination shows no abnormalities. An x-ray of the chest shows a 2.5-cm noncalcified pulmonary nodule in the right upper lobe. A CT scan of the chest confirms the x-ray findings. An x-ray of the chest obtained 1 year ago showed no abnormalities. Which of the following is the most appropriate next step in diagnosis?

- (A) Measurement of serum calcium concentration
- (B) Second x-ray of the chest in 6 weeks
- (C) Ventilation-perfusion lung scans
- (D) Bronchoscopy with transbronchial biopsy
- (E) Median sternotomy

19. A 57-year-old woman comes to the physician for a routine follow-up examination. She has a 5-year history of hypertension treated with captopril. She has had a 6.8-kg (15-lb) weight gain since her last visit 1 year ago; she is 165 cm (5 ft 5 in) tall and currently weighs 72 kg (160 lb); BMI is 27 kg/m². Her temperature is 37°C (98.6°F), pulse is 88/min, respirations are 14/min, and blood pressure is 160/86 mm Hg. The lungs are clear to auscultation. Cardiac examination shows no abnormalities. The abdomen is soft and nontender with no palpable masses. Pedal pulses and sensation to pinprick are diminished bilaterally. Fasting serum studies show a total cholesterol concentration of 240 mg/dL and glucose concentration of 182 mg/dL. Which of the following is the most likely cause of these findings?

- (A) Abnormal insulin secretion with insulin resistance
- (B) Autoimmune β-cell destruction
- (C) Excess glycogen breakdown
- (D) Excess release of glucagon and catecholamines
- (E) Insulin allergy

20. A 3-year-old girl is brought to the emergency department because of left leg pain after falling at preschool 2 hours ago. She has a history of fractures after minor trauma. She has consistently been at the 10th percentile for height and weight since birth. Examination shows blue sclerae. There is an obvious deformity of the left thigh. An x-ray shows a new fracture of the left femur and evidence of previous fracturing. Which of the following is the most likely cause of these findings?

- (A) Child abuse
- (B) Defective type I collagen
- (C) Deficient sulfate ion transport
- (D) Hypocalcemia
- (E) Hypophosphatemia
- (F) Vitamin D deficiency

Answer Form for Surgery Sample Questions

(Questions 1-20)

- | | |
|-----------|-----------|
| 1. _____ | 11. _____ |
| 2. _____ | 12. _____ |
| 3. _____ | 13. _____ |
| 4. _____ | 14. _____ |
| 5. _____ | 15. _____ |
| 6. _____ | 16. _____ |
| 7. _____ | 17. _____ |
| 8. _____ | 18. _____ |
| 9. _____ | 19. _____ |
| 10. _____ | 20. _____ |

Answer Key for Surgery Sample Questions

(Questions 1-20)

- | | | | |
|-----|---|-----|---|
| 1. | C | 11. | E |
| 2. | A | 12. | A |
| 3. | E | 13. | D |
| 4. | A | 14. | B |
| 5. | D | 15. | E |
| 6. | A | 16. | B |
| 7. | A | 17. | D |
| 8. | A | 18. | D |
| 9. | B | 19. | A |
| 10. | E | 20. | B |

COMPREHENSIVE BASIC SCIENCE

The Comprehensive Basic Science Examination is a general, integrated achievement test covering material typically learned during basic science education, with somewhat more emphasis on second-year courses in medical schools with traditional curricula. The exam reflects content coverage on USMLE Step 1 and uses the same item formats.

System

General Principles	25%–35%
Individual Organ Systems	65%–75%
Hematopoietic & lymphoreticular	
Central & peripheral nervous	
Skin & related connective tissue	
Musculoskeletal	
Respiratory	
Cardiovascular	
Gastrointestinal	
Renal/urinary	
Reproductive	
Endocrine	
Immune	

Process

Normal	25%–45%
Abnormal	30%–50%
Principles of therapeutics	15%–25%
Psychosocial, cultural, occupational, and environmental considerations	5%–10%

-
- In a steady state, the difference in CO₂ content between the venous blood leaving a tissue and the arterial blood entering the tissue is determined by which of the following ratios?
 - Alveolar ventilation to tissue blood flow
 - Alveolar ventilation to tissue O₂ consumption
 - Tissue CO₂ production to tissue blood flow
 - Tissue CO₂ production to tissue O₂ consumption
 - Tissue CO₂ production to venous P_{CO₂}
 - A 16-month-old boy is brought to the physician by his mother for a well-child examination. His mother expresses concern that he did not walk until the age of 14 months, whereas his older sister walked at the age of 10 months. Physical examination shows no abnormalities. Which of the following best explains this patient's condition?
 - Autistic disorder
 - Child abuse
 - Oppositional defiant disorder
 - Sensory integration disorder
 - Normal development
 - A 77-year-old woman is visited by the home care nurse who notes that the patient is more lethargic than usual. Her skin and mucous membranes are dry. An increase in the serum concentration or activity of which of the following provides the strongest indication that the patient is dehydrated?
 - Albumin
 - Alkaline phosphatase
 - Bilirubin
 - Calcium
 - Uric acid
 - A male newborn delivered at 26 weeks' gestation develops respiratory distress immediately after a spontaneous vaginal delivery. His respirations are 40/min. Physical examination shows cyanosis and lower rib retractions with respiration. Heart sounds are normal. Bilateral breath sounds are heard on auscultation. A chest x-ray shows bilateral lung opacities. The most likely cause of this patient's breathing difficulties is insufficient production of which of the following substances?
 - Collagen, type III
 - α-Fetoprotein
 - Meconium
 - Retinoic acid
 - Surfactant

5. A 28-year-old woman, gravida 1, para 1, comes to the physician because of progressive fatigue since delivering a male newborn 6 months ago. She is sleeping 8 to 10 hours nightly, but she is still tired during the day. She also has not had a menstrual period since her pregnancy. Pregnancy was complicated during the third trimester by severe bleeding from placenta previa. She required multiple blood transfusions during the cesarean delivery, but she did well after the delivery. She was unable to breast-feed her newborn because of poor milk production. Which of the following is the most likely diagnosis?
- (A) Anemia
(B) Cardiomyopathy
(C) Major depressive disorder
(D) Postpartum pituitary infarction
(E) Thyroiditis
6. A 12-year-old African American boy is brought to the physician by his mother because of a swollen right earlobe for 3 weeks. He had the ear pierced at a local mall 6 weeks ago. The swelling has persisted despite removal of the earring 3 weeks ago. The mother developed a thick rubbery scar on her abdomen after a cesarean delivery 12 years ago. His temperature is 37°C (98.6°F). Physical examination shows a nontender, flesh-colored swelling of the right earlobe. The skin is intact over the swelling, and it is soft and nontender. There is no cervical lymphadenopathy. Which of the following is the most likely cause of the swelling in this patient?
- (A) Bacterial infection
(B) Contact dermatitis
(C) Foreign body
(D) Keloid
(E) Lipoma
7. A 5-year-old boy is brought to the physician by his parents because of an 8-month history of difficulty walking. His parents say that he limps when he walks and has a waddling gait; he also has difficulty standing. When getting up from a sitting position, he uses his hands to walk up his thighs and push his body into a standing position. His parents have not noticed any weakness of his arms. His mother is an only child, but she has an uncle who became bedridden as a child and died of respiratory arrest. Physical examination shows prominent calf muscles. Muscle strength is 4/5 at both hips but normal elsewhere. This patient most likely has a mutation in the gene coding for which of the following proteins?
- (A) Actin
(B) Dystrophin
(C) Frataxin
(D) Myelin
(E) Myosin
8. A 27-year-old man comes to the physician because of pain with urination for 3 days. He has had no fever or chills. He is sexually active with three partners and does not use condoms consistently. He began having sexual relations with his most recent partner 1 week ago. His temperature is 37°C (98.6°F). Physical examination shows no abnormalities except for a clear, watery urethral discharge. Urinalysis shows 10–20 WBC/hpf but no bacteria. Which of the following is the most likely causal organism?
- (A) *Chlamydia trachomatis*
(B) *Entamoeba histolytica*
(C) *Escherichia coli*
(D) *Helicobacter pylori*
(E) *Shigella flexneri*
9. A 20-year-old college student develops fever, severe pharyngitis, hepatosplenomegaly, and lymphadenopathy. The pathogenesis of this syndrome most likely involves a double-stranded DNA virus infection of which of the following cells?
- (A) B lymphocytes
(B) Kupffer cells
(C) Macrophages
(D) Neutrophils
(E) T lymphocytes
10. A 2-year-old boy with Down syndrome is brought to the physician by his mother for a follow-up examination. His blood pressure is increased in the upper extremities and decreased in the lower extremities. Physical examination shows cyanosis of the lower extremities. An AP x-ray of the chest shows notching of the inferior surfaces of the 3rd through 8th ribs. The diagnosis of left ventricular hypertrophy is suspected. Which of the following is the most likely underlying abnormality in this patient?
- (A) Atrial septal defect
(B) Coarctation of the aorta
(C) Persistent truncus arteriosus
(D) Tetralogy of Fallot
(E) Transposition of the great arteries
11. A 1-day-old neonate has hemolytic disease of the newborn. The parents are both Rh-positive, but IgG isoagglutinins are found in the mother's blood. Which of the following parental blood types is most likely to cause this condition?
- | | Mother | Father |
|-----|--------|--------|
| (A) | A | O |
| (B) | AB | O |
| (C) | B | A |
| (D) | B | O |
| (E) | O | AB |

12. A previously healthy 42-year-old woman comes to the emergency department because of progressive shortness of breath and intermittent cough productive of blood-tinged sputum for 10 days. She has no history of major medical illness and takes no medications. Her respirations are 24/min. Diffuse rhonchi are heard in both lung fields on auscultation. A chest x-ray shows patchy opacities bilaterally. Laboratory studies show:

Serum creatinine	2.5 mg/dL
Urine	
Protein	3+
RBC	3+
RBC casts	numerous

A serum anti-glomerular basement membrane autoantibody assay is positive. Which of the following is the most likely diagnosis?

- (A) Goodpasture syndrome
- (B) Hemolytic uremic syndrome
- (C) Löffler syndrome
- (D) Mucocutaneous lymph node syndrome (Kawasaki disease)
- (E) Wegener granulomatosis

13. A 10-year-old boy is found to have mild iron deficiency anemia. His mother informs the physician that the family members belong to a religious denomination that does not consume meat. Her son refuses to eat dark green vegetables or to take vitamin pills, stating that they make him feel nauseated. It is most appropriate for the physician to ask the mother which of the following questions next?

- (A) "Are you concerned that if you let him get away with not eating right when he's 10, he'll be more likely to give you trouble when he's a teenager?"
- (B) "Can you tell me exactly why your religion prohibits meat?"
- (C) "Would you like information on other iron rich foods consistent with a vegetarian diet?"
- (D) "Would you like me to write a note to your religious leader requesting a medical exemption from your dietary requirements?"
- (E) "Wouldn't your son rather eat spinach than get an iron shot every week?"

14. A 45-year-old man is diagnosed with gastroesophageal reflux disease. Omeprazole treatment is initiated. Which of the following is the mechanism of action of this drug?

- (A) Binds to H₂ receptors
- (B) Creates a cytoprotective layer in the stomach
- (C) Inhibits H⁺-K⁺ ATPase
- (D) Prevents absorption of dietary acids
- (E) Stimulates serotonin receptors

15. A 64-year-old man comes to the physician because of a 3-day history of painful rash over his right flank. Three days before the rash appeared, he had pain in the same area. His temperature is 37.4°C (99.3°F), pulse is 78/min, respirations are 17/min, and blood pressure is 130/70 mm Hg. Physical examination shows clustered lesions in a band-like area over the right flank. The lesions have an erythematous base and are crusted. Which of the following is the most likely causal virus?

- (A) Cytomegalovirus
- (B) Epstein-Barr virus
- (C) Human papillomavirus
- (D) Kaposi sarcoma virus
- (E) Varicella-zoster virus

16. A 27-year-old man with AIDS is brought to the hospital 30 minutes after having a seizure. He currently takes no medications. A CT scan of the head shows multiple ring-enhancing lesions. Which of the following is the most likely diagnosis?

- (A) Amoebiasis
- (B) Cysticercosis
- (C) Echinococcosis
- (D) Schistosomiasis
- (E) Toxoplasmosis
- (F) Trichinosis

17. An investigator has conducted an experiment to determine whether certain environmental exposure morbidity is eliminated if a person carries a specific allele of three different genes on three separate chromosomes. The frequencies of an individual having the allele for these respective genes are 0.6, 0.2, and 0.1. All three alleles are necessary to confer protection. The probability that a randomly selected individual will have all three alleles is closest to which of the following?

- (A) 0.900
- (B) 0.600
- (C) 0.200
- (D) 0.100
- (E) 0.012

18. A health inspector confiscates chickens smuggled into Taiwan from mainland China after she discovers them in the hold of a ship. Testing shows that, although the chickens appear healthy, they are infected with the H5N1 subtype of the influenza A virus. Which of the following is the primary concern for human health from these virus-infected chickens?

- (A) Mutation of the virus to a form that causes fatal encephalitis
- (B) Mutation of the virus to a form that causes fatal renal disease
- (C) Mutation of the virus to a form that is highly infectious among humans
- (D) Secretion of a product that will cause immunosuppression in those that eat the meat
- (E) Secretion of a product that will cause mutations of the virus in the fetuses of mothers that eat the meat
- (F) Secretion of a product that will make the meat of the chicken poisonous to eat

19. A 35-year-old woman has hypertension and truncal obesity. Serum studies show:

Cortisol (AM)	100 µg/dL (N=5–20)
Cortisol (PM)	100 µg/dL (N=2.5–10)
ACTH (AM)	100 pg/mL (N=20–100)
Cortisol 8 h after 1 mg dexamethasone	95 µg/dL
Cortisol 8 h after 8 mg dexamethasone	30 µg/dL

Which of the following is the most likely cause of this woman's increased serum cortisol concentration?

- (A) Adrenocortical adenoma
- (B) Ectopic corticotropin-releasing hormone producing neoplasm
- (C) Ectopic corticotropin-secreting neoplasm
- (D) Pituitary microadenoma
- (E) Self-administration of synthetic glucocorticoids

20. A 42-year-old woman comes to the physician for a routine health maintenance examination. She says that she feels fine. She is 170 cm (5 ft 7 in) tall and weighs 86 kg (190 lb); BMI is 30 kg/m². Her blood pressure is 131/82 mm Hg. Physical examination shows no other abnormalities. Fasting serum studies show:

Glucose	105 mg/dL
Cholesterol, total	210 mg/dL
Triglycerides	185 mg/dL
C-reactive protein	0.35 mg/L (N=0.08–3.1)

This patient is at increased risk for developing which of the following conditions?

- (A) Atherosclerosis
- (B) Chronic lymphocytic (Hashimoto) thyroiditis
- (C) Systemic lupus erythematosus
- (D) Systemic sclerosis (scleroderma)
- (E) Type 1 diabetes mellitus

Answer Form for Comprehensive Basic Science Sample Questions

(Questions 1-20)

1. _____
2. _____
3. _____
4. _____
5. _____
6. _____
7. _____
8. _____
9. _____
10. _____

11. _____
12. _____
13. _____
14. _____
15. _____
16. _____
17. _____
18. _____
19. _____
20. _____

Answer Key for Comprehensive Basic Science Sample Questions

(Questions 1-20)

- | | | | |
|-----|---|-----|---|
| 1. | C | 11. | E |
| 2. | E | 12. | A |
| 3. | A | 13. | C |
| 4. | E | 14. | C |
| 5. | D | 15. | E |
| 6. | D | 16. | E |
| 7. | B | 17. | E |
| 8. | A | 18. | C |
| 9. | A | 19. | D |
| 10. | B | 20. | A |

COMPREHENSIVE CLINICAL SCIENCE

The Comprehensive Clinical Science Examination is a general, integrated achievement test covering material typically learned during core clinical clerkships. The exam reflects content coverage on USMLE Step 2 and uses the same item formats.

<i>Normal Growth and Development and General Principles of Care</i>	10%–20%
<i>Organ Systems</i>	80%–90%
Immunologic Disorders	
Diseases of the Blood and Blood-forming Organs	
Mental Disorders	
Diseases of the Nervous System and Special Senses	
Cardiovascular Disorders	
Diseases of the Respiratory System	
Nutritional and Digestive Disorders	
Gynecologic Disorders	
Renal, Urinary, and Male Reproductive System	
Disorders of Pregnancy, Childbirth, and the Puerperium	
Disorders of the Skin and Subcutaneous Tissues	
Diseases of the Musculoskeletal System and Connective Tissue	
Endocrine and Metabolic Disorders	
<i>Physician Tasks</i>	
Promoting Health and Health Maintenance	15%–20%
Understanding Mechanisms of Disease	20%–35%
Establishing a Diagnosis	25%–40%
Applying Principles of Management	15%–25%

1. A clinical trial of a potentially valuable medical treatment is planned. It is unlikely that it will directly benefit the study subjects but very likely that it will benefit future patients. There is a risk for short-term minor gastric discomfort but essentially no risk for long-term adverse effects. The investigator concludes that disclosure of the risks may discourage participation in the trial. Which of the following is the most appropriate next step?
 - (A) Proceed with the trial only with disclosure, because informed consent is an absolute requirement
 - (B) Proceed with the trial only with disclosure, because the trial will not directly benefit the subjects
 - (C) Proceed with the trial using only subjects who agree to participate without disclosure
 - (D) Proceed with the trial without disclosure, because the probability of long-term harm to subjects is remote
 - (E) Proceed with the trial without disclosure, because the risks to subjects are outweighed by the possible benefits to many patients
2. A 25-year-old man comes to the emergency department because of a 1-month history of fever, chills, nonproductive cough, and progressive shortness of breath; he now becomes short of breath after walking 20 feet. He has had a 4.5-kg (10-lb) weight loss during this period. He has not seen a physician for 10 years, and he takes no medications. He has a 10-year history of intravenous heroin use and shares needles. He is in mild respiratory distress while sitting. His temperature is 38.6°C (101.4°F), pulse is 92/min, respirations are 24/min, and blood pressure is 110/70 mm Hg. Pulse oximetry on room air shows an oxygen saturation of 90%. There is no jugular venous distention. Diffuse crackles are heard bilaterally. There is no peripheral edema. An x-ray of the chest shows diffuse interstitial infiltrates bilaterally. This patient is most likely to have which of the following immunologic abnormalities?
 - (A) Decreased B-lymphocyte count
 - (B) Decreased CD4+ T-lymphocyte count
 - (C) Decreased serum complement concentrations
 - (D) Decreased serum IgA concentration
 - (E) Decreased splenic opsonization
 - (F) IgG autoantibodies

3. A 27-year-old man is brought to the emergency department 20 minutes after his roommate found him unconscious on their bathroom floor. The patient has a history of intravenous heroin use. He has no history of serious illness and takes no medications. On arrival, he appears cyanotic. He is unresponsive to verbal and painful stimuli. His temperature is 37.1°C (98.8°F), pulse is 80/min, respirations are 4/min, and blood pressure is 110/60 mm Hg. Examination shows new and old needle tracks over the upper and lower extremities. Cardiopulmonary examination shows no abnormalities. Arterial blood gas analysis on room air shows:

pH	7.20
PCO ₂	80 mm Hg
PO ₂	50 mm Hg
HCO ₃ ⁻	29 mEq/L

Which of the following is the best explanation for this patient's hypoxemia?

- (A) Decreased inspired oxygen tension
- (B) Hypoventilation
- (C) Impaired diffusion capacity of the lung for carbon monoxide
- (D) Right-to-left shunt
- (E) Ventilation-perfusion mismatch

-
4. A 15-year-old boy has had pain in the knee since sustaining an injury in a high school football game 6 weeks ago. The high school trainer has been treating him with heat and ultrasound, without significant improvement. Physical examination shows tenderness of the medial femur approximately 7.5 cm above the joint. There is no ligamentous instability, joint swelling, or effusion. Which of the following is the most appropriate next step in diagnosis?

- (A) Anteroposterior and lateral x-rays
- (B) Arthrography
- (C) Arthroscopy
- (D) Measurement of serum calcium concentration
- (E) Ultrasonography

5. A 2-week-old boy is brought to the physician because of a 3-day history of persistent discharge from his eyes. He was born at term following an uncomplicated pregnancy and delivery. Examination of the eyes shows tarsal inflammation and a thin mucopurulent discharge. Testing of scrapings from the tarsal conjunctivae is positive for *Chlamydia trachomatis*. The remainder of the examination shows no abnormalities. Which of the following is the most likely mode of transmission of this patient's infection?

- (A) Aerosol exposure
- (B) Contact with maternal cervical secretions
- (C) Exposure to household pets
- (D) Poor hand washing by caregivers
- (E) Transplacental transmission

6. A 62-year-old man comes to the physician because of blood in his urine for 24 hours. Vital signs are within normal limits. Examination shows no abnormalities. Tissue obtained on bladder biopsy shows transitional cell carcinoma. Abstinence from which of the following is most likely to have prevented this condition?

- (A) Alcohol
- (B) Coffee
- (C) Diet soda
- (D) Tea
- (E) Tobacco

7. A 21-year-old nulligravid woman who is not using contraception has had irregular menstrual periods since menarche at age 13 years. She has noted increased hair growth on her face and lower abdomen. On pelvic examination, there is copious cervical mucus and slightly enlarged irregular ovaries. Which of the following is the most likely cause of these findings?

- (A) Adrenal adenoma
- (B) Idiopathic hirsutism
- (C) Ovarian tumor
- (D) Pituitary adenoma
- (E) Polycystic ovarian syndrome

8. A 50-year-old man has a 1-hour history of unremitting chest pressure and "gassiness." He has no history of cardiac problems but does have a history of peptic ulcer disease. Physical examination shows no abnormalities except for a blood pressure of 140/80 mm Hg. Which of the following is the most appropriate initial step in diagnosis?
- (A) Test of the stool for occult blood
 - (B) ECG
 - (C) X-ray series of the upper gastrointestinal tract
 - (D) Echocardiography
 - (E) Endoscopy of the upper gastrointestinal tract
9. A 32-year-old nulligravid woman comes to the physician because of a 20-minute episode of shortness of breath when she awoke this morning. Her only medication is an oral contraceptive. She has smoked one pack of cigarettes daily for 10 years. She is sexually active with multiple partners. Physical examination shows erythema, swelling, warmth, and tenderness behind the right knee; a cord-like mass can be palpated. Which of the following is the most likely diagnosis?
- (A) Corticosteroid-induced arthritis
 - (B) Gonococcal arthritis
 - (C) Pulmonary embolism
 - (D) Steroid-induced asthma
 - (E) Systemic lupus erythematosus
10. A 4030-g (8-lb 14-oz) newborn has internal rotation of the left upper extremity at the shoulder, extension at the elbow, pronation of the forearm, and flexion of the fingers following a low forceps delivery. He was born at term following an uncomplicated pregnancy. Passive range of motion of the left upper extremity is full; the newborn does not cry or grimace when the left arm, shoulder, or clavicle is palpated. Examination shows no other abnormalities. Which of the following is the most likely underlying mechanism of this condition?
- (A) Anterior dislocation of the left shoulder
 - (B) An inherited skeletal dysostosis
 - (C) Intracerebral hemorrhage
 - (D) Posterior dislocation of the cervical vertebrae
 - (E) Traction on the brachial plexus during delivery
11. A 72-year-old man comes for a routine health maintenance examination. He has a 5-year history of progressive difficulty falling asleep at night and waking up early in the morning. He has not had snoring, nightmares, or changes in appetite or weight. He has felt energized since starting a new business venture 8 months ago. He has hypertension treated with hydrochlorothiazide. He does not smoke cigarettes, drink alcohol, or use illicit drugs. His blood pressure is 145/88 mm Hg. The lungs are clear to auscultation. Cardiac examination shows an S₄ gallop. Laboratory studies are within normal limits. Which of the following is the most likely cause of this patient's insomnia?
- (A) Hypertension
 - (B) Hyperthyroidism
 - (C) Major depressive disorder
 - (D) Malignancy
 - (E) Sleep apnea
 - (F) Normal aging
12. A 15-year-old boy with a recent diagnosis of acute lymphocytic leukemia is scheduled to undergo chemotherapy. Initially, he is eager to begin treatment, but after discussing possible adverse effects of chemotherapy with his parents and physician, he refuses to undergo treatment. Which of the following is the most appropriate next step in management?
- (A) Ask the patient why he refuses to undergo treatment
 - (B) Tell the patient that he is refusing treatment because he is denying the seriousness of his illness
 - (C) Recommend projective psychological testing
 - (D) Begin behavior therapy for oppositional behavior
 - (E) Proceed with chemotherapy
 - (F) Begin clonazepam therapy
13. A 22-year-old woman comes to the physician because of a 1-year history of intermittent lower abdominal cramps associated with bloating and mild nausea. The cramps are occasionally associated with constipation and bowel movements relieve the pain. She has not had any other symptoms. She has no history of serious illness and takes no medications. Her last menstrual period was 2 weeks ago. She appears well. Abdominal examination shows mild diffuse tenderness to palpation. Which of the following is the most likely diagnosis?
- (A) Crohn disease
 - (B) Irritable bowel syndrome
 - (C) Meckel diverticulum
 - (D) Peptic ulcer disease
 - (E) Ulcerative colitis

14. A 10-year retrospective study is conducted to determine factors that could predispose women to have children with complex congenital heart disease. A total of 1000 women were asked whether they had flu-like symptoms during their first trimester. The investigators found that women who had children with complex congenital heart disease were five times more likely than women with healthy newborns to report flu-like symptoms in their first trimester. Which of the following features of this study is most likely to affect the validity of this conclusion?
- (A) Assessment bias
 - (B) Case mix bias
 - (C) Random error
 - (D) Recall bias
 - (E) Selection bias
15. An asymptomatic 32-year-old woman comes to the physician for a follow-up examination. She has a 10-month history of hypertension that has been difficult to control with medication. Current medications include metoprolol, lisinopril, hydrochlorothiazide, and nifedipine. Her blood pressure today is 170/110 mm Hg. Abdominal examination shows a bruit in the left upper quadrant. Which of the following is the most likely cause of this patient's hypertension?
- (A) Coarctation of the aorta
 - (B) Essential hypertension
 - (C) Hyperaldosteronism
 - (D) Hypercortisolism
 - (E) Hyperthyroidism
 - (F) Pheochromocytoma
 - (G) Pituitary adenoma
 - (H) Renal artery stenosis
16. Five days after falling and hitting her chest, a 55-year-old woman has acute midsternal chest pain that radiates to the back and is exacerbated by deep inspiration. Immediately following the accident, she had acute sternal pain that resolved in 1 day. Her temperature today is 37.7°C (99.9°F). A three-component scratchy sound is heard across the precordium. An x-ray of the chest shows a normal cardiac silhouette. An ECG shows diffuse ST-segment elevation and T-wave inversion. Which of the following is the most likely diagnosis?
- (A) Acute myocardial infarction
 - (B) Pleurodynia
 - (C) Purulent pericarditis
 - (D) Traumatic pericarditis
 - (E) Viral pericarditis
17. A 19-year-old primigravid woman comes to the physician for her first prenatal visit. Her last menstrual period was 18 weeks ago. Her pregnancy has been complicated by cocaine use. She has no history of serious illness and takes no medications. Her temperature is 36.7°C (98°F), pulse is 90/min, respirations are 16/min, and blood pressure is 110/50 mm Hg. Examination shows scleral icterus and poor dentition. The fundal height is 20 cm. The remainder of the examination shows no abnormalities. This patient is at greatest risk for which of the following conditions?
- (A) Abruptio placentae
 - (B) Gestational diabetes
 - (C) Macrosomia
 - (D) Pituitary infarction
 - (E) Postdates pregnancy
18. A 37-year-old woman comes to the emergency department 40 minutes after the onset of shortness of breath, dizziness, and an itchy rash. She says she feels a lump in her throat. Her symptoms began while she was eating at a restaurant buffet. She has an allergy to peanuts. She is alert but anxious and in respiratory distress. Her temperature is 37°C (98.6°F), pulse is 120/min, respirations are 30/min, and blood pressure is 75/50 mm Hg. Examination shows an urticarial rash on the trunk and extremities. There is swelling of the lips but no swelling of the tongue or pharynx. Diffuse wheezing is heard bilaterally. In addition to intravenous 0.9% saline and an antihistamine, which of the following drugs should be administered immediately?
- (A) Diazepam
 - (B) Dobutamine
 - (C) Epinephrine
 - (D) Phentolamine
 - (E) No additional pharmacotherapy is indicated
19. Two days after beginning primaquine for malaria prophylaxis, a 17-year-old African American boy is brought to the physician because of dark urine and yellowing of his eyes. His pulse is 88/min, respirations are 12/min, and blood pressure is 124/68 mm Hg. Examination shows scleral icterus and pale mucous membranes. His hemoglobin concentration is 10 g/dL. A blood smear shows erythrocyte fragments and Heinz bodies. Which of the following is the most likely explanation for these findings?
- (A) Decreased porphobilinogen deaminase activity
 - (B) Decreased production of β -globin chains
 - (C) Deficiency of glucose 6-phosphate dehydrogenase
 - (D) Deficiency of glycosylphosphatidylinositol
 - (E) Fragmentation of erythrocytes by fibrin strands

20. A 17-year-old boy comes to the physician because he believes that his penis is too large. He has been uncomfortable with the size of his genitals since he underwent puberty 4 years ago. He is concerned that people will see the bulge of his genitals under his clothing. Although he has never had sexual intercourse, he is afraid that his size will make it difficult or painful for most women. He plays intramural basketball but no longer undresses in front of teammates or uses public showers. He has not had changes in sleep or appetite. He has no history of serious illness and takes no medications. He occasionally drinks one or two beers on weekends but uses no illicit drugs. He continues to receive mostly B and C grades in school. He is 183 cm (6 ft) tall and weighs 68 kg (150 lb); BMI is 20 kg/m². Genital development is Tanner stage 4. Physical examination shows no abnormalities. On mental status examination, he appears embarrassed, and he describes his mood as "okay." Which of the following is the most likely diagnosis?

- (A) Body dysmorphic disorder
- (B) Delusional disorder
- (C) Hypoactive sexual desire disorder
- (D) Narcissistic personality disorder
- (E) Schizoid personality disorder
- (F) Sexual aversion disorder
- (G) Social phobia

Answer Form for Comprehensive Clinical Science Sample Questions

(Questions 1-20)

- | | |
|-----------|-----------|
| 1. _____ | 11. _____ |
| 2. _____ | 12. _____ |
| 3. _____ | 13. _____ |
| 4. _____ | 14. _____ |
| 5. _____ | 15. _____ |
| 6. _____ | 16. _____ |
| 7. _____ | 17. _____ |
| 8. _____ | 18. _____ |
| 9. _____ | 19. _____ |
| 10. _____ | 20. _____ |

Answer Key for Comprehensive Clinical Science Sample Questions

(Questions 1-20)

- | | | | |
|-----|---|-----|---|
| 1. | A | 11. | F |
| 2. | B | 12. | A |
| 3. | B | 13. | B |
| 4. | A | 14. | D |
| 5. | B | 15. | H |
| 6. | E | 16. | D |
| 7. | E | 17. | A |
| 8. | B | 18. | C |
| 9. | C | 19. | C |
| 10. | E | 20. | A |

INTRODUCTION TO CLINICAL DIAGNOSIS

<i>General Principles</i>	15%–20%
Human development and genetics	1%–5%
Gender, ethnic, and behavioral considerations affecting disease treatment and prevention	10%–15%
Progression through life cycle	1%–5%
Psychologic and social factors influencing patient behavior	1%–5%
Patient interviewing, consultation, and interactions with the family	5%–10%
Medical ethics, jurisprudence, and professional behavior	1%–5%
Nutrition	1%–5%
<i>Organ Systems</i>	80%–85%
Hematopoietic & lymphoreticular	1%–5%
Central & peripheral nervous	15%–20%
Skin & related connective tissue	1%–5%
Musculoskeletal	5%–10%
Respiratory	10%–15%
Cardiovascular	15%–20%
Gastrointestinal	10%–15%
Renal/urinary	1%–5%
Reproductive	5%–10%
Endocrine	1%–5%

- A 6-month-old boy is brought to the physician because of left knee swelling for 24 hours. Three months ago, he had three large hematomas on his forehead that resolved without treatment. His two sisters and his mother have no history of similar symptoms. His mother's maternal uncle and her brother died before the age of 30 years of massive cerebral hemorrhages. Physical examination shows deep ecchymoses over the buttocks and severe swelling of the left knee. The most likely explanation for these findings is a deficiency of which of the following?

 - Factor I (fibrinogen)
 - Factor V (proaccelerin)
 - Factor VIII (antihemophilic factor)
 - Factor XIII (transglutaminase)
 - von Willebrand factor
- A 56-year-old man has had a small, slowly growing nodule on his chin during the past 3 years. The lesion is 1.3 cm in diameter, the center is ulcerated, and the border is waxy. Examination of tissue obtained on excision of the lesion is most likely to show which of the following?

 - Actinic keratosis
 - Basal cell carcinoma
 - Melanoma
 - Seborrheic keratosis
 - Squamous cell carcinoma
- A 23-year-old woman comes to the physician because of a 5-month history of intermittent discharge from both breasts. Her last menstrual period was 6 months ago. She takes no medications and is otherwise healthy. She has never been sexually active. Physical examination shows scant white fluid expressible from the breasts bilaterally. Serum studies are most likely to show an increase in which of the following hormone concentrations?

 - Estradiol
 - Follicle-stimulating hormone
 - Luteinizing hormone
 - Progesterone
 - Prolactin
 - Testosterone
- A 39-year-old man has the acute onset of pain, corneal clouding, and diffuse redness in the left eye. There is no discharge. Vision is 20/20 in the right eye and 20/100 in the left eye. The left pupil is dilated. Which of the following is the most likely cause of these findings?

 - Acute glaucoma
 - Acute hordeolum
 - Bacterial conjunctivitis
 - Corneal abrasion
 - Subconjunctival hemorrhage

5. A 27-year-old man with a sleep disorder enrolls in a research study. During sleep evaluation, he is noted to snore loudly and stop breathing for prolonged periods of 30 to 40 seconds. Toward the end of one of these apneic periods, arterial blood gas analysis is done. Which of the following sets of findings is most likely in this patient?

	pH	PCO ₂	PO ₂
(A)	Increased	decreased	normal
(B)	Normal	increased	increased
(C)	Normal	decreased	increased
(D)	Decreased	increased	decreased
(E)	Decreased	decreased	normal

6. A 65-year-old woman comes to the physician because of a 2-day history of a high temperature, chills, and headache. She was diagnosed with multiple myeloma 6 months ago. Her temperature is 39°C (102.2°F), pulse is 90/min, and blood pressure is 150/80 mm Hg. Examination shows lethargy and severe neck rigidity; no other abnormalities are noted. Which of the following organisms is most likely to be found on Gram stain of cerebrospinal fluid?

- (A) *Haemophilus influenzae*
- (B) *Listeria monocytogenes*
- (C) *Neisseria meningitidis*
- (D) *Pseudomonas aeruginosa*
- (E) *Streptococcus pneumoniae*

7. A 55-year-old man who is a farmer is brought to the emergency department 30 minutes after his wife found him unresponsive in their barn. She reports that he was foaming at the mouth and had evidence of tearing of the eyes, vomiting, and diarrhea. He is unresponsive to painful stimuli. His pulse is 45/min, and blood pressure is 90/60 mm Hg. Bilateral diffuse wheezes are heard on auscultation of the chest. This patient has most likely sustained poisoning by which of the following?

- (A) Carbon monoxide
- (B) Ethanol
- (C) Ethylene glycol
- (D) Methanol
- (E) Organophosphate

8. A 28-year-old female executive has irresistible urges to sleep during the day. She often has episodes of dropping her head, slurred speech, and suddenly dropping things from her hands, all lasting for seconds to minutes. In addition, she frequently has vivid, colorful dreams just before falling asleep. Occasionally, when in certain emotionally charged situations, she feels like her whole body goes limp; however, she remembers everything. Which of the following is the most likely diagnosis?

- (A) Absence seizures
- (B) Delayed sleep phase syndrome
- (C) Insomnia
- (D) Narcolepsy
- (E) Night terrors

9. A 15-year-old girl is brought to the physician by her mother for a follow-up examination. She has a 3-year history of seizure disorder treated with topiramate. Her mother says, "I am worried because she's refused to take her medication since she started dating this new guy. She won't even tell me why." Physical examination shows no abnormalities. After the mother is asked to leave the room, which of the following is the most appropriate statement by the physician to begin a discussion of this patient's lack of adherence to her medication regimen?

- (A) "Can you tell me why you don't want to take your medication anymore?"
- (B) "I would like to discuss the serious consequences that could result from your not taking your medication."
- (C) "I'm worried that your boyfriend isn't a good influence on you."
- (D) "Perhaps I can talk to your boyfriend about your condition so that you can take your medication again."
- (E) "Since you are still a minor, you must respect your mother's decision and take your medication."

10. A 78-year-old woman is brought to the physician because of a headache and visual problems for 4 days. The headache is more severe on the left side, in the area above and in front of her ear. She has had intermittent fevers, difficulty chewing, and a 4.5-kg (10-lb) weight loss during the past 6 weeks. Her temperature is 37.4°C (99.4°F). Visual fields are decreased. There is tenderness to palpation on the left side of the scalp. Which of the following is the most likely diagnosis?

- (A) Acute meningitis
- (B) Cluster headache
- (C) Idiopathic intracranial hypertension
- (D) Migraine
- (E) Subarachnoid hemorrhage
- (F) Temporal arteritis
- (G) Tension-type headache

11. A 65-year-old man comes to the physician because of a 6-week history of fatigue and difficulty swallowing; he also has had a 6.8-kg (15-lb) weight loss during this period. Ten years ago, he underwent operative resection of squamous cell carcinoma of the floor of the mouth. He takes no medications. He has smoked 2 packs of cigarettes daily for 40 years and drinks 60 oz of alcohol weekly. Physical examination shows a nontender abdomen with bowel sounds present. The physician suspects a second primary cancer. This cancer is most likely located at which of the following sites?
- (A) Brain
 - (B) Esophagus
 - (C) Liver
 - (D) Lymph nodes
 - (E) Stomach
12. A previously healthy 34-year-old woman had a single rigor 3 days ago. Since then she has had temperatures to 38.9°C (102°F), shortness of breath with minimal exertion, and cough productive of rust-colored sputum. An x-ray of the chest shows consolidation in the right lower lobe of the lung. Which of the following is the most likely diagnosis?
- (A) Mycoplasmal pneumonia
 - (B) Pneumococcal pneumonia
 - (C) Pseudomonas pneumonia
 - (D) Toxoplasmosis
 - (E) Tuberculosis
13. A 35-year-old woman comes to the physician because of abdominal pain for 6 months. She has not had fever, nausea, or vomiting. She has no history of major medical illness. She takes no medications. She does not smoke cigarettes or drink alcohol. Physical examination shows ecchymoses in various stages of healing over the upper and lower extremities. There are acute hematomas around the wrists. Test of the stool for occult blood is negative. A pregnancy test result is negative. It is most appropriate for the physician to ask which of the following questions to begin a discussion with this patient about the possibility of physical abuse?
- (A) "Can you tell me how you received these bruises?"
 - (B) "What do you think about making an appointment with a social worker?"
 - (C) "Why do you stay with someone who physically abuses you?"
 - (D) "Why don't you tell me why you really came to see me?"
 - (E) "Would you like me to report whoever did this to you to the authorities?"
14. A 22-year-old football player is brought to the emergency department 1 hour after he sustained a left leg injury during a tackle. Physical examination shows mild tenderness and anterior instability of the tibia with the knee in 90 degrees of flexion (positive drawer sign). Active range of motion of the left knee is limited by pain. Which of the following best explains these findings?
- (A) Hemarthrosis
 - (B) Patellar fracture
 - (C) Tear of the anterior cruciate ligament
 - (D) Tear of the medial ligament
 - (E) Tear of the medial meniscus
15. A postmenopausal 60-year-old woman comes to the physician because of a 2-year history of vaginal dryness, intermittent vaginal pain, and decreased pleasure with sexual intercourse. Vital signs are within normal limits. Abdominal examination shows no abnormalities. Pelvic examination shows pale, dry vaginal mucosa. No masses are palpated. Which of the following is the most appropriate next step in management?
- (A) Advise the patient that since these problems are expected for a woman her age, the risks associated with pharmacotherapy outweigh any benefits
 - (B) Explain to the patient that it will be important to assess the impact of her condition on her husband as further treatment is initiated
 - (C) Inform the patient that she should accept her symptoms as part of the normal aging process
 - (D) Inform the patient that these problems are often psychological and that she would benefit from psychotherapy
 - (E) Reassure the patient that her symptoms are common among women her age and that there are treatments available
16. A 73-year-old woman is brought to the emergency department because of severe back pain for 1 day. She has had no recent falls or trauma to the area. Menopause occurred at the age of 52 years. Her temperature is 37°C (98.6°F), pulse is 92/min, and blood pressure is 140/92 mm Hg. Physical examination shows spinal tenderness at T8. A spinal x-ray shows fractures at T8 and T10. Which of the following is the most likely underlying cause of this patient's condition?
- (A) Osteitis deformans (Paget disease)
 - (B) Osteomalacia
 - (C) Osteoporosis
 - (D) Pott disease
 - (E) Spinal metastasis

17. An 18-year-old man comes to the physician because of nausea, headache, blood in his urine, and malaise for 2 days. Three weeks ago, he had severe pharyngitis that resolved spontaneously after several days without antibiotic therapy. His blood pressure is 165/88 mm Hg. Physical examination shows mild peripheral edema. His serum creatinine concentration is 2.1 mg/dL, and serum CH50 concentration is markedly decreased. Urinalysis shows:

Protein	2+
RBC	25–50/hpf
WBC	10–20/hpf
RBC casts	present

Which of the following is the most likely diagnosis?

- (A) Goodpasture syndrome
 - (B) IgA nephropathy
 - (C) Malignant hypertension
 - (D) Post-streptococcal glomerulonephritis
 - (E) Wegener granulomatosis
18. A 60-year-old woman comes to the physician because of a 3-month history of abdominal fullness and increasing abdominal girth with vague lower quadrant pain. Abdominal examination shows distention. Pelvic examination shows a 10-cm, hard, irregular, nontender, right adnexal mass. Which of the following is the most appropriate statement by the physician at this time?
- (A) “Do you have any friends or family members with you today who could join us before I tell you the diagnosis?”
 - (B) “I’m concerned about something I found during the examination today. Let’s talk about what needs to be done to figure out what it is.”
 - (C) “I’m not sure whether there is something abnormal in your pelvis. You’ll need to undergo a pelvic ultrasonography for further study.”
 - (D) “It looks like you have ovarian cancer, but we’ll need to do further tests to be sure.”
 - (E) “Unfortunately, I need to refer you to a cancer specialist because you have some abnormal examination findings.”

19. A 26-year-old woman comes to the emergency department because of a 12-hour history of lower abdominal pain and vaginal bleeding. There is no history of medical illness, and she takes no medications. Her temperature is 37°C (98.6°F), pulse is 125/min, respirations are 40/min, and blood pressure is 96/64 mm Hg. Abdominal examination shows distention and tenderness. Decreased bowel sounds are heard. Pelvic examination shows an adnexal mass on the right. Measurement of which of the following is the most appropriate next step in management of this patient?

- (A) Leukocyte count
- (B) Platelet count
- (C) Prothrombin time
- (D) Serum α -fetoprotein concentration
- (E) Serum β -human chorionic gonadotropin concentration

20. A 25-year-old woman with stable cystic fibrosis meets inclusion criteria for a placebo-controlled industry-sponsored research study on a new treatment. The primary care physician is not part of the research team, but he is familiar with the research and considers it to be scientifically sound. The research protocol provides medication and medical care limited to assessing medication effects and adverse effects for 6 months. The patient knows of the study and asks the physician if she should enroll. Which of the following is the most appropriate initial response by the primary care physician?

- (A) Advise against participation because the research is funded by a pharmaceutical company
- (B) Provide the patient with basic information about the study, and ask if she would like to learn more from the research team
- (C) Strongly recommend to the patient that she participate in the study because it will benefit future generations
- (D) Tell the patient that if she enrolls in the study, he will not be able to provide any medical care for her during this study

Answer Form for Introduction to Clinical Diagnosis Sample Questions

(Questions 1-20)

- | | |
|-----------|-----------|
| 1. _____ | 11. _____ |
| 2. _____ | 12. _____ |
| 3. _____ | 13. _____ |
| 4. _____ | 14. _____ |
| 5. _____ | 15. _____ |
| 6. _____ | 16. _____ |
| 7. _____ | 17. _____ |
| 8. _____ | 18. _____ |
| 9. _____ | 19. _____ |
| 10. _____ | 20. _____ |

Answer Key for Introduction to Clinical Diagnosis Sample Questions

(Questions 1-20)

- | | | | |
|-----|---|-----|---|
| 1. | C | 11. | B |
| 2. | B | 12. | B |
| 3. | E | 13. | A |
| 4. | A | 14. | C |
| 5. | D | 15. | E |
| 6. | E | 16. | C |
| 7. | E | 17. | D |
| 8. | D | 18. | B |
| 9. | A | 19. | E |
| 10. | F | 20. | B |

AMBULATORY MEDICINE

ADULT AMBULATORY MEDICINE

<i>General Principles</i>	1%–5%
<i>Organ Systems</i>	
Immunologic Disorders	5%–10%
Diseases of the Blood	5%–10%
Diseases of the Nervous System	1%–5%
Cardiovascular Disorders	15%–20%
Diseases of the Respiratory System	10%–15%
Nutritional and Digestive Disorders	10%–15%
Gynecologic Disorders	1%–5%
Renal, Urinary, Male Reproductive Systems	5%–10%
Diseases of the Skin	1%–5%
Musculoskeletal and Connective Tissue Disorders	5%–10%
Endocrine and Metabolic Disorders	5%–10%
<i>Physician Tasks</i>	
Promoting Health and Health Maintenance	10%–15%
Understanding Mechanisms of Disease	15%–20%
Establishing a Diagnosis	40%–45%
Applying Principles of Management	20%–25%

ADULT/PEDIATRIC AMBULATORY MEDICINE

<i>General Principles</i>	5%–10%
<i>Organ Systems</i>	
Immunologic Disorders	5%–10%
Diseases of the Blood	5%–10%
Mental Disorders	1%–5%
Diseases of the Nervous System	5%–10%
Cardiovascular Disorders	10%–15%
Diseases of the Respiratory System	5%–10%
Nutritional and Digestive Disorders	10%–15%
Gynecologic Disorders	1%–5%
Renal, Urinary, Male Reproductive Systems	5%–10%
Diseases of the Skin	5%–10%
Musculoskeletal and Connective Tissue Disorders	5%–10%
Endocrine and Metabolic Disorders	5%–10%
<i>Physician Tasks</i>	
Promoting Health and Health Maintenance	10%–15%
Understanding Mechanisms of Disease	15%–20%
Establishing a Diagnosis	40%–45%
Applying Principles of Management	20%–25%

ADULT AMBULATORY MEDICINE

1. A 19-year-old man has had fever, headache, sore throat, and swelling of the cervical lymph nodes for 5 days. His temperature is 40°C (104°F), pulse is 120/min, respirations are 20/min, and blood pressure is 125/85 mm Hg. The pharynx is red and swollen with enlarged tonsils and exudate. There is tender cervical adenopathy and palpable lymph nodes in the axillary and inguinal areas. The spleen tip is palpable. Leukocyte count is 14,000/mm³ (25% segmented neutrophils, 60% atypical lymphocytes, and 15% monocytes). A throat culture is obtained. Which of the following is the most likely pathogen?

 - (A) Adenovirus
 - (B) Cytomegalovirus
 - (C) Epstein-Barr virus
 - (D) Group A streptococcus
 - (E) *Toxoplasma gondii*
2. An asymptomatic 37-year-old African American man comes to the physician for a preemployment examination. He has no history of serious illness and takes no medications. He does not smoke. He exercises regularly. His mother and 40-year-old brother have hypertension. He is 178 cm (5 ft 10 in) tall and weighs 73 kg (162 lb); BMI is 23 kg/m². His pulse is 82/min, and blood pressure is 144/92 mm Hg. Examination shows no other abnormalities. Which of the following is the most appropriate next step?

 - (A) Routine examination in 1 year
 - (B) Decreased dietary intake of sodium
 - (C) 24-Hour urine collection for measurement of catecholamines
 - (D) Second measurement of blood pressure in 2 weeks
 - (E) Exercise stress test
3. A 32-year-old woman comes to the physician because of lethargy and boredom since the birth of her son 5 months ago. She worries about her ability to care for him and has had frequent palpitations. She is unable to fall back asleep after nighttime feedings. She stopped breast-feeding 1 month ago. Her son is healthy, and growth and development are normal for his age. Her pulse is 58/min, respirations are 18/min, and blood pressure is 122/80 mm Hg. Physical examination shows no abnormalities. She remembers one of three objects after 5 minutes. Her serum cholesterol concentration is 265 mg/dL. The most appropriate next step in diagnosis is measurement of which of the following serum concentrations?

 - (A) Cortisol
 - (B) Estrogen
 - (C) Progesterone
 - (D) Prolactin
 - (E) Thyroid-stimulating hormone
4. A 30-year-old woman comes to the physician for a routine examination. She has a 10-year history of type 1 diabetes mellitus. Examination shows normal findings. She has microalbuminuria; her hemoglobin A_{1c} is 7%, and serum creatinine concentration is 1.8 mg/dL. Which of the following is the most appropriate intervention?

 - (A) Administration of a calcium-channel blocking agent
 - (B) Administration of an angiotensin-converting enzyme (ACE) inhibitor
 - (C) Administration of an oral hypoglycemic agent
 - (D) Administration of aspirin daily
 - (E) Increase in the dose of insulin
5. A previously healthy 27-year-old woman comes to the physician because of a 3-month history of moderate abdominal pain that improves for a short time after she eats. She has not had any rectal bleeding. Her temperature is 36.4°C (97.5°F), pulse is 80/min, and blood pressure is 110/70 mm Hg. Abdominal examination shows midepigastria tenderness. Her hemoglobin concentration is 12 g/dL, and leukocyte count is 8000/mm³. Serum *Helicobacter pylori* antibody assay is positive. Which of the following is the most appropriate next step in management?

 - (A) HIDA scan
 - (B) Amoxicillin, clarithromycin, and omeprazole therapy
 - (C) Ciprofloxacin therapy
 - (D) Omeprazole, magnesium hydroxide, and metoclopramide therapy
 - (E) Ranitidine therapy

Answer Form for Adult Ambulatory Medicine Sample Questions

(Questions 1-5)

1. _____
2. _____
3. _____
4. _____
5. _____

Answer Key for Adult Ambulatory Medicine Sample Questions

(Questions 1-5)

1. C
2. D
3. E
4. B
5. B

ADULT/PEDIATRIC AMBULATORY MEDICINE

1. A 19-year-old man has had fever, headache, sore throat, and swelling of the cervical lymph nodes for 5 days. His temperature is 40°C (104°F), pulse is 120/min, respirations are 20/min, and blood pressure is 125/85 mm Hg. The pharynx is red and swollen with enlarged tonsils and exudate. There is tender cervical adenopathy and palpable lymph nodes in the axillary and inguinal areas. The spleen tip is palpable. Leukocyte count is 14,000/mm³ (25% segmented neutrophils, 60% atypical lymphocytes, and 15% monocytes). A throat culture is obtained. Which of the following is the most likely pathogen?

 - (A) Adenovirus
 - (B) Cytomegalovirus
 - (C) Epstein-Barr virus
 - (D) Group A streptococcus
 - (E) *Toxoplasma gondii*
2. A 7-year-old girl is brought to the physician because of a 2-day history of fever, headache, sore throat, and swollen glands. She does not have a runny nose, congestion, or cough. She has no allergies to medications. Her temperature is 38.6°C (101.4°F), pulse is 120/min, respirations are 16/min, and blood pressure is 100/60 mm Hg. Examination shows a swollen, erythematous oropharynx with tonsillar exudates. The anterior cervical lymph nodes are enlarged and tender. No other abnormalities are noted. Which of the following is the most likely causal organism?

 - (A) Adenovirus
 - (B) *Corynebacterium diphtheriae*
 - (C) Group A streptococcus
 - (D) *Haemophilus influenzae*
 - (E) *Mycoplasma pneumoniae*
3. A healthy 16-year-old boy comes to the physician for an examination prior to participation in school sports. He is at the 90th percentile for height and 75th percentile for weight. His temperature is 37°C (98.6°F), pulse is 66/min, respirations are 16/min, and blood pressure is 145/95 mm Hg. Examination shows no other abnormalities. Which of the following is the most appropriate next step in management?

 - (A) Repeat blood pressure measurement in 2 weeks
 - (B) Recommend a low-sodium diet
 - (C) Recommend a weight loss program
 - (D) Begin diuretic therapy
 - (E) No further intervention indicated
4. A 14-year-old boy is brought to the physician because of constant right knee pain for 2 weeks. The pain is not relieved by rest or analgesics. There is no history of trauma. He is at the 50th percentile for height and above the 95th percentile for weight. He walks with a limp but is not in distress. His vital signs are within normal limits. Examination shows full range of motion of both knees; passive abduction and internal rotation of the right hip produce pain. There is no swelling of either knee or hip. Neurologic examination shows no abnormalities. Which of the following is the most likely diagnosis?

 - (A) Juvenile idiopathic arthritis
 - (B) Osgood-Schlatter disease
 - (C) Septic arthritis
 - (D) Slipped capital femoral epiphysis
 - (E) Toxic synovitis
5. A 27-year-old woman comes to the physician because of sad mood, tearfulness, lack of energy, decreased libido, feelings of worthlessness, and insomnia over the past month. During this period, she has had a 2.3-kg (5-lb) weight loss associated with a decreased appetite. She no longer takes pleasure in activities that she used to enjoy. There is no history of psychiatric illness. On mental status examination, she admits to hearing mumbling voices saying that she is “no good.” Her serum thyroid-stimulating hormone level is 0.5 µU/mL and free thyroxine index is 10 (N=4.2–13). Which of the following is the most likely diagnosis?

 - (A) Brief psychotic reaction
 - (B) Dysthymic disorder
 - (C) Major depressive disorder with psychotic features
 - (D) Major depressive disorder secondary to hyperthyroidism
 - (E) Schizoaffective disorder

Answer Form for Adult/Pediatric Ambulatory Medicine Sample Questions

(Questions 1-5)

1. _____
2. _____
3. _____
4. _____
5. _____

Answer Key for Adult/Pediatric Ambulatory Medicine Sample Questions

(Questions 1-5)

1. C
2. C
3. A
4. D
5. C

FAMILY MEDICINE MODULAR

<i>General Principles</i>	10%–15%
Infancy and childhood (normal growth and development)	
Adolescence (sexuality, separation from parents/autonomy; puberty)	
Senescence (normal physical and mental changes associated with aging)	
Medical Ethics and Jurisprudence	
Applied Biostatistics and Clinical Epidemiology	
Patient Safety	
<i>Organ Systems</i>	
Immunologic Disorders	1%–5%
Diseases of the Blood and Blood-forming Organs	1%–5%
Mental Disorders	5%–10%
Diseases of the Nervous System and Special Senses	5%–10%
Cardiovascular Disorders	10%–15%
Diseases of the Respiratory System	10%–15%
Nutritional and Digestive Disorders	10%–15%
Gynecologic Disorders	5%–10%
Renal, Urinary, and Male Reproductive System	5%–10%
Disorders of Pregnancy, Childbirth, and the Puerperium	1%–5%
Disorders of the Skin and Subcutaneous Tissues	1%–5%
Diseases of the Musculoskeletal System and Connective Tissue	5%–10%
(content allocation increases to 15%–20% with the addition of the Musculoskeletal module)	
Endocrine and Metabolic Disorders	5%–10%
<i>Physician Task</i>	
Promoting Health and Health Maintenance	15%–20%
Understanding Mechanisms of Disease	5%–10%
Establishing a Diagnosis	30%–35%
Applying Principles of Management	25%–30%
<i>Distribution Across Age Groups</i>	
Childhood	5%–15%
Adolescence	5%–10%
Adulthood	65%–75%
Geriatric	10%–15%

1. A 22-year-old college student comes to the physician because of a 2-month history of palpitations. She describes feeling shaky and nervous most of the time. She is a single mother and notes that her boyfriend has not helped with their infant daughter as much as he had promised. She is having difficulty taking care of her daughter and managing her schoolwork. She also has had a 4.5-kg (10-lb) weight loss despite a normal appetite. She is 165 cm (5 ft 5 in) tall and weighs 55 kg (120 lb); BMI is 20 kg/m². Her temperature is 37.4°C (99.4°F), pulse is 120/min, respirations are 18/min, and blood pressure is 150/70 mm Hg. Examination shows moist palms. The globes of the eyes are prominent with ptosis bilaterally. Neurologic examination shows a fine resting tremor of the hands. Deep tendon reflexes are 3+ with a shortened relaxation phase. Which of the following is the most likely diagnosis?
 - (A) Acute stress disorder
 - (B) Chronic lymphocytic thyroiditis (Hashimoto disease)
 - (C) Generalized anxiety disorder
 - (D) Graves disease
 - (E) Panic disorder
 - (F) Pheochromocytoma

2. A 62-year-old man comes to the physician because of pain and swelling of the right foot for 24 hours. There is no history of trauma. One month ago, he was diagnosed with hypertension and started treatment with hydrochlorothiazide. His temperature is 37.3°C (99.1°F), pulse is 86/min, and blood pressure is 150/90 mm Hg. Examination shows tenderness, swelling, erythema, and warmth of the right first metatarsophalangeal joint; range of motion is decreased. There is mild hallux valgus. Pedal pulses and sensation are intact. He walks with an antalgic gait. X-rays of the right foot show mild joint space narrowing and periarticular bony erosions of the metatarsophalangeal joint. Which of the following is the most appropriate next step in diagnosis?
 - (A) Venous Doppler ultrasonography
 - (B) Indium-labeled white blood cell scan
 - (C) MRI of the right foot
 - (D) Technetium 99m bone scan
 - (E) Joint aspiration

3. A 23-year-old man comes to the physician because of a 1-week history of painful urination and a clear urethral discharge. One month ago, he had similar symptoms and completed a course of doxycycline therapy for a chlamydial infection. He has no previous history of sexually transmitted diseases. He has been sexually active with one female partner for 2 years, and she takes an oral contraceptive. Examination shows no abnormalities. A urine polymerase chain reaction test is positive for *Chlamydia trachomatis*. Which of the following is the most likely explanation for this patient's current infection?
 - (A) Concurrent infection with *Neisseria gonorrhoeae*
 - (B) Doxycycline-resistant strain of *C. trachomatis*
 - (C) Insufficient duration of therapy
 - (D) Reacquisition of infection from his partner
 - (E) Sequestration of *C. trachomatis* in the epididymis

4. A 60-year-old man has had mild shortness of breath with exertion for 6 months. He has smoked two packs of cigarettes daily for 40 years. Examination shows mildly decreased breath sounds and prolonged expiratory time. Pulmonary function tests show an FEV₁ of 70%. If this patient stops smoking, which of the following best describes the 5-year course of his FEV₁?
 - (A) The FEV₁ will return to normal within 6 months
 - (B) The FEV₁ will return to normal within 5 years
 - (C) The FEV₁ will remain the same over time
 - (D) The FEV₁ will decrease at the same rate as a nonsmoker
 - (E) The FEV₁ will decrease at the same rate as a smoker

5. A 4-year-old girl is brought to the physician for a well-child visit. She feels well. She is at the 75th percentile for height and weight. Her temperature is 37°C (98.6°F), pulse is 100/min, respirations are 18/min, and blood pressure is 90/60 mm Hg. Cardiac examination shows a normal S₁ and S₂. There is a grade 2/6, systolic, vibratory ejection murmur heard best at the fourth intercostal space in the left midclavicular line. Which of the following is the most appropriate next step in management?
 - (A) Reexamination in 12 months
 - (B) Antistreptolysin O titer
 - (C) Complete blood count
 - (D) Chest x-ray
 - (E) Echocardiography

Answer Form for Family Medicine Modular Sample Questions

(Questions 1-5)

1. _____
2. _____
3. _____
4. _____
5. _____

Answer Key for Family Medicine Modular Sample Questions

(Questions 1-5)

1. D
2. E
3. D
4. D
5. A

EMERGENCY MEDICINE ADVANCED CLINICAL

General Principles including ethics and patient safety
*Organ systems**

1%–5%
95%–99%

Immunologic Disorders	
Diseases of the Blood	5%–10%
Mental Disorders	
Diseases of the Nervous System	10%–15%
Cardiovascular Disorders	15%–20%
Diseases of the Respiratory System	10%–15%
Nutritional and Digestive Disorders	10%–15%
Gynecologic Disorders	1%–5%
Renal, Urinary, Male Reproductive Systems	5%–10%
Obstetric Disorders	1%–5%
Disorders of the Skin	1%–5%
Disorders of the Musculoskeletal System and Connective Tissue	5%–10%
Endocrine and Metabolic Disorders	5%–10%

**A subset of items across the organ system section includes content that focuses on resuscitation/trauma (~15%) and environmental/toxicologic disorders (~15%).*

Physician Tasks

Promoting Health and Health Maintenance	1%–5%
Understanding Mechanisms of Disease	5%–10%
Establishing a Diagnosis	25%–35%
Applying Principles of Management	45%–55%

-
1. A 32-year-old woman comes to the emergency department 3 hours after the sudden onset of a severe headache. The pain is associated with nausea and vomiting. Medical history is noncontributory. She is drowsy but easy to arouse. Her temperature is 37.1°C (98.8°F), pulse is 92/min, respirations are 10/min, and blood pressure is 130/70 mm Hg. Examination of the head shows no abnormalities. Flexion of the neck produces pain. The optic fundi are normal. Motor and sensory examinations show no abnormalities. Cranial nerves are intact. Deep tendon reflexes are symmetric. Babinski sign is present bilaterally. Which of the following is most likely to confirm the diagnosis?
 - (A) X-rays of the sinuses
 - (B) Carotid duplex ultrasonography
 - (C) EEG
 - (D) CT scan of the head
 - (E) Biopsy of the temporal artery
 2. A 24-year-old nulligravid woman is brought to the emergency department after a syncopal episode at work. She has had progressively severe cramps in the lower abdomen over the past 6 hours. She has had spotty vaginal bleeding for 2 days; her last menstrual period began 7 weeks ago. She is diaphoretic and anxious. Her temperature is 37°C (98.6°F), pulse is 130/min, respirations are 26/min, and blood pressure is 80/60 mm Hg. Examination shows blood in the vaginal vault and diffuse abdominal tenderness; there is pain with cervical motion. Which of the following is the most appropriate next step in management?
 - (A) Intravenous administration of fluids
 - (B) Intravenous administration of broad-spectrum antibiotics
 - (C) Transfusion of O-negative blood
 - (D) Transfusion of type-specific blood
 - (E) Culdocentesis

3. A 15-month-old girl is brought to the emergency department after a generalized tonic-clonic seizure at home. The seizure stopped spontaneously after 2 minutes, and she seemed sleepy afterward. Her temperature prior to arrival was 39.6°C (103.2°F), and paramedics administered rectal acetaminophen. Her parents state that yesterday she had a mild runny nose but otherwise has been well. There is no personal or family history of serious medical illness or seizures. Development has been appropriate for age. On arrival, she is afebrile, alert, and interactive. Physical examination shows a supple neck. Neurologic examination shows no focal findings. Which of the following is the most appropriate next step in management?

- (A) Reassurance
- (B) CT scan of the head
- (C) Oral administration of phenobarbital
- (D) EEG
- (E) Lumbar puncture

4. An 18-year-old man is brought to the emergency department 10 minutes after he sustained a stab wound to his chest. On arrival, he is unresponsive to painful stimuli. His pulse is 130/min, respirations are 8/min and shallow, and palpable systolic blood pressure is 60 mm Hg. He is intubated and mechanically ventilated, and infusion of 0.9% saline is begun. After 5 minutes, his pulse is 130/min, and blood pressure is 70/40 mm Hg. Examination shows a 2-cm wound at the left sixth intercostal space at the midclavicular line. There is jugular venous distention. Breath sounds are normal. The trachea is at the midline. Heart sounds are not audible. Which of the following is the most likely cause of these findings?

- (A) Bronchial disruption
- (B) Hemothorax
- (C) Myocardial infarction
- (D) Pericardial tamponade
- (E) Tension pneumothorax

5. A 27-year-old man is brought to the emergency department 20 minutes after his roommate found him unconscious on their bathroom floor. The patient has a history of intravenous heroin use. He has no history of serious illness and takes no medications. On arrival, he appears cyanotic. He is unresponsive to verbal and painful stimuli. His temperature is 37.1°C (98.8°F), pulse is 80/min, respirations are 4/min, and blood pressure is 110/60 mm Hg. Examination shows new and old needle tracks over the upper and lower extremities. Cardiopulmonary examination shows no abnormalities. Arterial blood gas analysis on room air shows:

pH	7.20
PCO ₂	80 mm Hg
PO ₂	50 mm Hg
HCO ₃ ⁻	29 mEq/L

Which of the following is the best explanation for this patient's hypoxemia?

- (A) Decreased inspired oxygen tension
- (B) Hypoventilation
- (C) Impaired diffusion capacity of the lung for carbon monoxide
- (D) Right-to-left shunt
- (E) Ventilation-perfusion mismatch

Answer Form for Emergency Medicine Advanced Clinical Sample Questions

(Questions 1-5)

1. _____
2. _____
3. _____
4. _____
5. _____

Answer Key for Emergency Medicine Advanced Clinical Sample Questions

(Questions 1-5)

1. D
2. A
3. A
4. D
5. B

INTERNAL MEDICINE ADVANCED CLINICAL

<i>General Principles</i>	5%–10%
<i>Organ Systems</i>	
Immunologic Disorders	5%–10%
Diseases of the Blood	5%–10%
Mental Disorders	1%–5%
Diseases of the Nervous System	5%–10%
Cardiovascular Disorders	15%–20%
Diseases of the Respiratory System	10%–15%
Nutritional and Digestive Disorders	10%–15%
Renal, Urinary, Male Reproductive Systems	5%–10%
Diseases of the Skin	1%–5%
Musculoskeletal and Connective Tissue Disorders	1%–5%
Endocrine and Metabolic Disorders	5%–10%
<i>Physician Tasks</i>	
Promoting Health and Health Maintenance	5%–10%
Understanding Mechanisms of Disease	5%–10%
Establishing a Diagnosis	35%–45%
Applying Principles of Management	40%–50%

1. A previously healthy 67-year-old man is admitted to the hospital because of lethargy, confusion, muscle cramps, and decreased appetite for 7 days. He appears ill. His temperature is 37°C (98.6°F), pulse is 98/min, respirations are 20/min, and blood pressure is 120/70 mm Hg. Breath sounds are diminished at the right lung base. Neurologic examination shows no abnormalities except for lethargy. Serum studies show:

Na ⁺	114 mEq/L
K ⁺	4.3 mEq/L
Creatinine	1 mg/dL
Thyroid-stimulating hormone	4.1 μU/mL

An x-ray of the chest shows a 2-cm nodule in the right lower lobe and mediastinal adenopathy. A biopsy specimen of the nodule is most likely to show which of the following?

- (A) Adenocarcinoma
- (B) Clear cell carcinoma
- (C) Mesothelioma
- (D) Small cell carcinoma
- (E) Squamous cell carcinoma

2. A 67-year-old woman is brought to the emergency department because of severe chest pain 4 hours after undergoing outpatient endoscopy and dilatation of an esophageal stricture caused by reflux. At discharge, she reported no chest pain. Three hours later, she vomited a small amount of blood and had severe pain. She is pale. Her temperature is 38°C (100.4°F), pulse is 125/min, respirations are 22/min, and blood pressure is 140/85 mm Hg. Examination shows crepitus in the neck and moderate epigastric tenderness. The lungs are clear to auscultation, and breath sounds are equal bilaterally. Rectal examination shows no masses; test of the stool for occult blood is positive. Which of the following is the most likely cause of these symptoms?
- (A) Bleeding from erosive esophagitis
 - (B) Esophageal perforation
 - (C) Mallory-Weiss syndrome
 - (D) Myocardial infarction
 - (E) Perforated gastric ulcer
3. A 72-year-old woman is brought to the emergency department 1 hour after the sudden onset of right facial droop and weakness of the right arm and leg. She takes captopril for hypertension and daily aspirin. Her pulse is 80/min, respirations are 16/min, and blood pressure is 150/90 mm Hg. Examination shows a left carotid bruit and right central facial paralysis. There is moderate expressive aphasia. A CT scan of the head shows no abnormalities. Which of the following is the most appropriate initial pharmacotherapy?
- (A) Oral ticlopidine
 - (B) Oral warfarin
 - (C) Sublingual nifedipine
 - (D) Intravenous nitroprusside
 - (E) Intravenous tissue plasminogen activator
4. One day after undergoing cholecystectomy, a 37-year-old man becomes increasingly tremulous and anxious. He is irritable with the staff and moves around restlessly in bed. He has no previous history of serious medical illness and takes no medications. He does not smoke. His temperature is 37.4°C (99.4°F), pulse is 120/min, and blood pressure is 160/100 mm Hg. Physical examination shows a well-healing incision without erythema. He is oriented to person but not to place or time. Administration of which of the following is the most appropriate next step in management?
- (A) Intravenous ceftriaxone
 - (B) Oral buspirone
 - (C) Oral diazepam
 - (D) Oral naltrexone
 - (E) Oral phentolamine
 - (F) Oral sertraline
5. Fourteen hours after admission to the hospital for treatment of severe hypertension, a 32-year-old woman has stridor. On admission, she was given captopril. She appears anxious. Her pulse is 140/min, respirations are 32/min, and blood pressure is 140/85 mm Hg. Examination shows swelling of the lips and tongue. Diffuse stridorous wheezes are heard on auscultation. There is diminished air movement. Which of the following is the most appropriate next step in management?
- (A) Observation only
 - (B) Measurement of serum captopril concentration
 - (C) Measurement of serum IgE concentration
 - (D) X-ray of the chest
 - (E) Tracheal intubation

Answer Form for Internal Medicine Advanced Clinical Sample Questions

(Questions 1-5)

1. _____
2. _____
3. _____
4. _____
5. _____

Answer Key for Internal Medicine Advanced Clinical Sample Questions

(Questions 1-5)

1. D
2. B
3. E
4. C
5. E

SURGERY ADVANCED CLINICAL

<i>General Principles</i>	5%–10%
<i>Organ Systems</i>	
Immunologic Disorders	1%–5%
Diseases of the Blood	1%–5%
Diseases of the Nervous System	1%–5%
Cardiovascular Disorders	10%–15%
Diseases of the Respiratory System	10%–15%
Nutritional and Digestive Disorders	15%–20%
Gynecologic Disorders	1%–5%
Renal, Urinary, Male Reproductive Systems	5%–10%
Obstetric Disorders	1%–5%
Diseases of the Skin	1%–5%
Musculoskeletal and Connective Tissue Disorders	10%–15%
Endocrine and Metabolic Disorders	5%–10%
<i>Physician Tasks</i>	
Promoting Health and Health Maintenance	1%–5%
Understanding Mechanisms of Disease	5%–10%
Establishing a Diagnosis	30%–40%
Applying Principles of Management	40%–50%

1. A 67-year-old woman is hospitalized because of abdominal pain and persistent copious vomiting for 24 hours. Two weeks ago, she was hospitalized for treatment of atrial fibrillation; after cardioversion to a normal sinus rhythm, she began treatment with warfarin. Yesterday at a follow-up visit, her INR was 6, and her medication was discontinued. She takes no other medications. Her temperature is 37°C (98.6°F), pulse is 120/min and regular, respirations are 20/min, and blood pressure is 100/78 mm Hg. The abdomen is distended and moderately tender; there is voluntary guarding in the epigastrium. There are no masses, organomegaly, or obvious hernias. Rectal examination shows no abnormalities. Test of the stool for occult blood is negative. Her hemoglobin concentration has decreased from 13 g/dL yesterday to 7.8 g/dL today. An ECG shows a normal sinus rhythm. Which of the following is the most likely explanation for this patient's abdominal symptoms?
- (A) Internal small-bowel herniation
 - (B) Intestinal ischemia from a cardiac embolus
 - (C) Intramural hematoma of the proximal small bowel
 - (D) Intussusception of the small bowel
 - (E) Malrotation of the small bowel

2. Six hours after undergoing surgical excision of the distal colon for cancer, a 77-year-old man has decreased urine output. His urine output has been 10 mL/h during the past 3 hours. During the 4-hour operation, he lost 500 mL of blood and underwent transfusion of 1 unit of packed red blood cells. His initial postoperative course was uncomplicated. Two years ago, he had a myocardial infarction and underwent coronary artery bypass grafting. He has a 10-year history of hypertension well controlled with atenolol. Current medications include morphine and labetalol. He currently appears pale and diaphoretic. His temperature is 37°C (98.6°F), pulse is 85/min, respirations are 14/min, and blood pressure is 90/60 mm Hg. Pulse oximetry on 2 L/min of oxygen via nasal cannula shows an oxygen saturation of 89%. Cardiopulmonary examination shows no abnormalities. The abdomen is nondistended with mild tenderness over the incision. His hematocrit is 24%, serum sodium concentration is 140 mEq/L, and serum creatinine concentration is 2.1 mg/dL. The patient is switched to administration of 100% oxygen by a nonbreathing face mask. The most appropriate next step in management is administration of which of the following?
- (A) Bumetanide
 - (B) 5% Dextrose in water
 - (C) Fresh frozen plasma
 - (D) Furosemide
 - (E) Packed red blood cells
 - (F) 0.45% Saline
3. A 16-month-old boy is brought to the emergency department because of 2- to 3-minute episodes of acute abdominal pain over the past 6 hours. During the episodes, he turns pale, screams, and draws up his knees. He has also passed one bloody stool. A mass is palpated in the right upper quadrant of the abdomen. Which of the following is the most appropriate next step in management?
- (A) Nothing by mouth; administration of fluids and antibiotics, intravenously
 - (B) Water-soluble contrast enema
 - (C) CT scan of the abdomen
 - (D) Colonoscopy
 - (E) Laparotomy
4. A 37-year-old man is brought to the emergency department after his motorcycle ran into the back of a truck at high speed. He was wearing a helmet. On arrival, his neck is immobilized in a cervical collar, and intravenous fluids are being administered. Paramedics report that at the scene he appeared to be intoxicated. He is alert and talking. His breath smells of alcohol. His pulse is 130/min, respirations are 30/min, and blood pressure is 100/60 mm Hg. The lungs are clear to auscultation. Heart sounds are normal. The abdomen is distended and tender. There is blood at the urethral meatus. Ultrasonography shows blood in the abdomen. An x-ray of the pelvis shows fractures of the pubic rami and ischial and ilial fractures on the right. Which of the following is the most appropriate next step in management?
- (A) Cystography
 - (B) Intravenous pyelography
 - (C) Retrograde urethrography
 - (D) Placement of a urinary catheter
 - (E) Diagnostic peritoneal lavage
5. A 57-year-old hospitalized man undergoes right subclavian venous catheterization for hyperalimentation. He is currently being treated for a small bowel fistula. While the results of an x-ray of the chest to check the catheter position are pending, the patient suddenly becomes agitated. His pulse is 110/min, and blood pressure is 70/50 mm Hg. Examination shows jugular venous distention. The lungs are clear to auscultation. Breath sounds are equal bilaterally. The trachea is midline. An x-ray of the chest shows a catheter in the superior vena cava, transversing the right ventricle and crossing to the left of the midline. Which of the following is the most likely cause of this patient's hypotension?
- (A) Air embolism
 - (B) Pericardial tamponade
 - (C) Pulmonary artery perforation
 - (D) Staphylococcal bacteremia
 - (E) Tension pneumothorax

Answer Form for Surgery Advanced Clinical Sample Questions

(Questions 1-5)

1. _____
2. _____
3. _____
4. _____
5. _____

Answer Key for Surgery Advanced Clinical Sample Questions

(Questions 1-5)

1. C
2. E
3. B
4. C
5. B

PEDIATRICS ADVANCED CLINICAL

<i>General Principles</i>	5%–10%
<i>Organ Systems</i>	
Immunologic Disorders	1%–5%
Diseases of the Blood	5%–10%
Mental Disorders	1%–5%
Diseases of the Nervous System	10%–15%
Cardiovascular Disorders	5%–10%
Diseases of the Respiratory System	10%–15%
Nutritional and Digestive Disorders	10%–15%
Gynecologic Disorders	1%–5%
Renal, Urinary, Male Reproductive Systems	5%–10%
Diseases of the Skin	1%–5%
Musculoskeletal and Connective Tissue Disorders	5%–10%
Endocrine and Metabolic Disorders	5%–10%
 <i>Physician Tasks</i>	
Promoting Health and Health Maintenance	1%–5%
Understanding Mechanisms of Disease	15%–20%
Establishing a Diagnosis	30%–40%
Applying Principles of Management	35%–45%

1. A 15-month-old girl is brought to the emergency department after a generalized tonic-clonic seizure at home. The seizure stopped spontaneously after 2 minutes, and she seemed sleepy afterward. Her temperature prior to arrival was 39.6°C (103.2°F), and paramedics administered rectal acetaminophen. Her parents state that yesterday she had a mild runny nose but otherwise has been well. There is no personal or family history of serious medical illness or seizures. Development has been appropriate for age. On arrival, she is afebrile, alert, and interactive. Physical examination shows a supple neck. Neurologic examination shows no focal findings. Which of the following is the most appropriate next step in management?
- (A) Reassurance
 - (B) CT scan of the head
 - (C) Oral administration of phenobarbital
 - (D) EEG
 - (E) Lumbar puncture

2. A previously healthy 15-year-old boy is brought to the emergency department 30 minutes after the onset of headache, nausea, and dizziness. He had been practicing football twice daily in outside temperatures of 100°F. On arrival, he is alert and cooperative. His temperature is 39°C (102.2°F), pulse is 120/min, respirations are 28/min, and blood pressure is 90/60 mm Hg. Examination shows profuse diaphoresis. Mental status examination shows no abnormalities. Which of the following is the most likely diagnosis?
- (A) Heat cramps
 - (B) Heat exhaustion
 - (C) Heat stroke
 - (D) Malignant hyperthermia
 - (E) Neuroleptic malignant syndrome
3. A 3-month-old boy is brought to the emergency department because of a 3-day history of vomiting and diarrhea. He has a low-pitched cry and responds only to painful stimuli. His temperature is 35.2°C (95.4°F), pulse is 203/min, respirations are 48/min, and blood pressure is 52/35 mm Hg. Peripheral pulses are barely palpable. Capillary refill time is delayed. Administration of 100% oxygen by nasal cannula is begun. Multiple attempts at establishing peripheral intravenous access are unsuccessful. Which of the following is the most appropriate next step in management?
- (A) Oral rehydration
 - (B) Intramuscular injections of antibiotics
 - (C) Intubation and mechanical ventilation
 - (D) Placement of a nasogastric tube
 - (E) Placement of an intraosseous catheter
4. A previously healthy 12-year-old girl is brought to the emergency department because of a 4-day history of sore throat that has become progressively worse during the past 2 days. She also has had malaise and an earache on the right during this time. She now has difficulty eating because of the pain but has had no vomiting or diarrhea. Her voice sounds muffled. Her temperature is 38.7°C (101.7°F). There is right cervical lymphadenopathy. Examination of the mouth is difficult to perform because of pain; the right tonsil appears enlarged, and the uvula is deviated to the left. Examination of the tympanic membranes shows no abnormalities. Which of the following is the most likely diagnosis?
- (A) Bacterial tracheitis
 - (B) Peritonsillar abscess
 - (C) Retropharyngeal abscess
 - (D) Tonsillar hypertrophy
 - (E) Tonsillitis
5. A 15-year-old boy is brought to the emergency department 2 hours after the onset of severe left scrotal pain that began while he was playing ice hockey. There is no history of trauma. Over the past year, he has had several episodes of mild left scrotal discomfort that have resolved spontaneously. The left side of the scrotum is enlarged, erythematous, and exquisitely tender. The left testicle is higher in the scrotum compared with the right. Which of the following is the most likely underlying cause of this patient's condition?
- (A) Failure of the testicle to fully descend
 - (B) Lack of fixation of the testicle to the tunica vaginalis
 - (C) Overactive cremasteric reflex
 - (D) Patent processus vaginalis
 - (E) Presence of an appendix testis

Answer Form for Pediatric Advanced Clinical Sample Questions

(Questions 1-5)

1. _____
2. _____
3. _____
4. _____
5. _____

Answer Key for Pediatric Advanced Clinical Sample Questions

(Questions 1-5)

1. A
2. B
3. E
4. B
5. B